ERKNet

Non-cystinotic Fanconi syndrome

Francesco Emma

Division of Nephrology and Dialysis
Bambino Gesù Children's Hospital, IRCCS - Rome, Italy

Bambino Gesù
OSPEDALE PEDIATRICO

De Toni – Debre - Fanconi Syndrome

- **Fanconi G.** Die nicht diabetischen Glykosurien und Hyperglykaemien des aelteren Kindes. *Jahrbuch fuer Kinderheilkunde 1931; 133: 257–300* → Renal glycosuria
- **de Toni G.** Remarks on the relationship between renal rickets (renal dwarfism) and renal diabetes. *Acta Pediatrica 1933; 16: 479–484* → Rickets & glycosuria
- **Debre R, Marie J, Cleret F et Messimy R.** Rachitisme tardif coexistant avec une Nephrite chronique et une Glycosurie. *Archive de Medicine des Enfants 1934; 37: 597–606* → Rickets & glycosuria & nephropathy
- **Fanconi G.** Der nephrotisch-glykosurische Zwergwuchs mit hypophosphataemischer Rachitis. *Deutsche Medizinische Wochenschrift 1936; 62: 1169–1171* → Rickets & glycosuria & nephropathy

Proximal tubular cell and Fanconi syndrome

Isolated apical transporter defects
Rarely Fanconi sd

Mutations of transcription factors
Rarely Fanconi sd

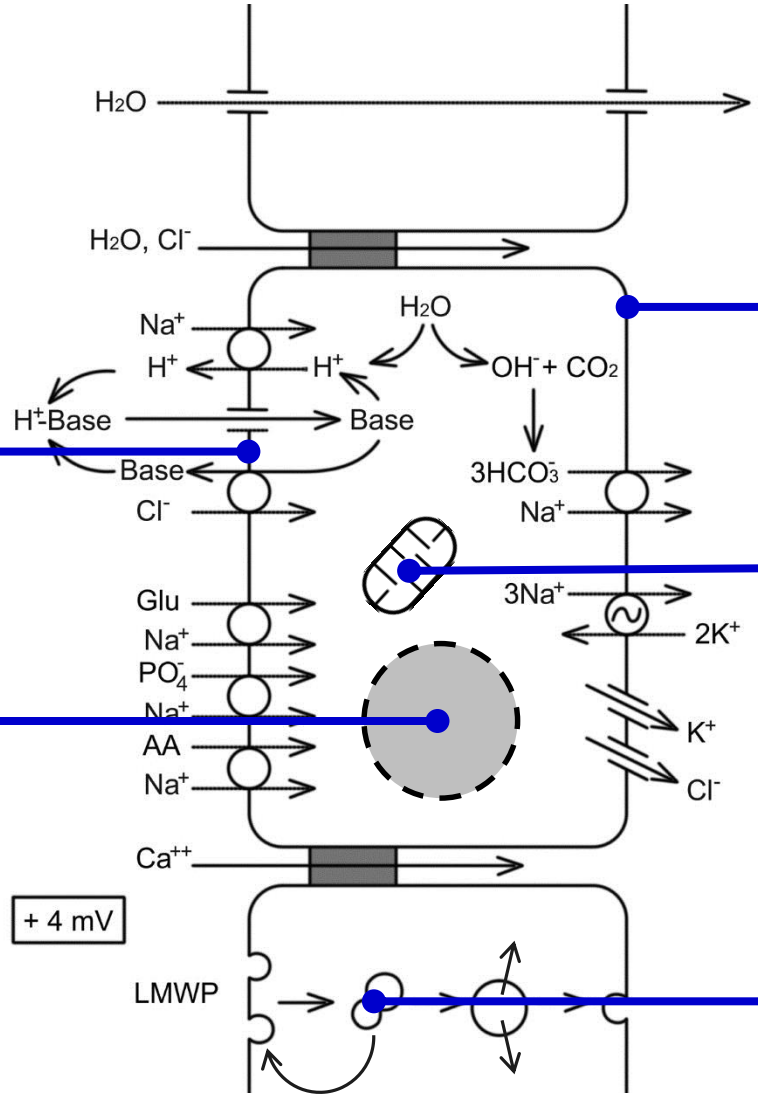

Isolated baso-lateral transporter defects
Possible Fanconi sd

Energy depletion / metabolic failure
Frequent Fanconi sd

Impaired receptor-mediated endocytosis
- receptor mutations
  no / mild Fanconi sd
- intracellular trafficking defects
  frequent Fanconi sd

Genetic forms of Fanconi Syndrome

METABOLIC DISEASES

- **Galactosemia**
  (GALT) cataract, liver disease, vomiting, diarrhea, encephalopathy
- **Fructose Intolerance**
  (ALDOB) hypoglycaemia, vomiting, liver disease
- **Thyrosinemia**
  (FAH) liver disease, poor growth
- **Wilson disease**
  (ATP7B) liver disease, encephalopathy, Kayser-Fleischer rings
- **Mitochondrial cytopathies**

MEMBRANE TRANSPORTERS TRANSCRIPTION FACTORS

- **Fanconi-Bickel**
  (GLUT2) hypoglycemia, liver disease, rickets, failure to thrive
- **Lysinuric protein intolerance**
  (SLC7A7) failure to thrive, hepatosplenomegaly, respiratory failure, immunological disorders
- **AD Fanconi Syndrome**
  (R76W HNF4α)
  neonatal iperinsulinism, MODY1, macrosomia

Unknown cause: "idiopathic Fanconi syndrome"

RECEPTOR-MEDIATED ENDOCYTOSIS

- **Imerslund-Gräsbeck syndrome**
  (CUB, AMN)
- **Donnai-Barrow syndrome**
  (LPR2)
- **Cystinosis**
  (CTNS)
- **Lowe syndrome**
  (OCRL1)
- **Dent disease**
  (CLCN5, OCRL1)
- **ARC syndrome**
  (VPS33B, VIPAR) joint contractures, cholestasis, ichthyosis, CNS malformation, platelet anomalies

Renal tubular disorders in mitochondrial disorders

Renal Fanconi syndrome

Renal tubular acidosis

Isolated hyperaminoaciduria

Isolated hypomagnesemia

Barrter-like phenotype

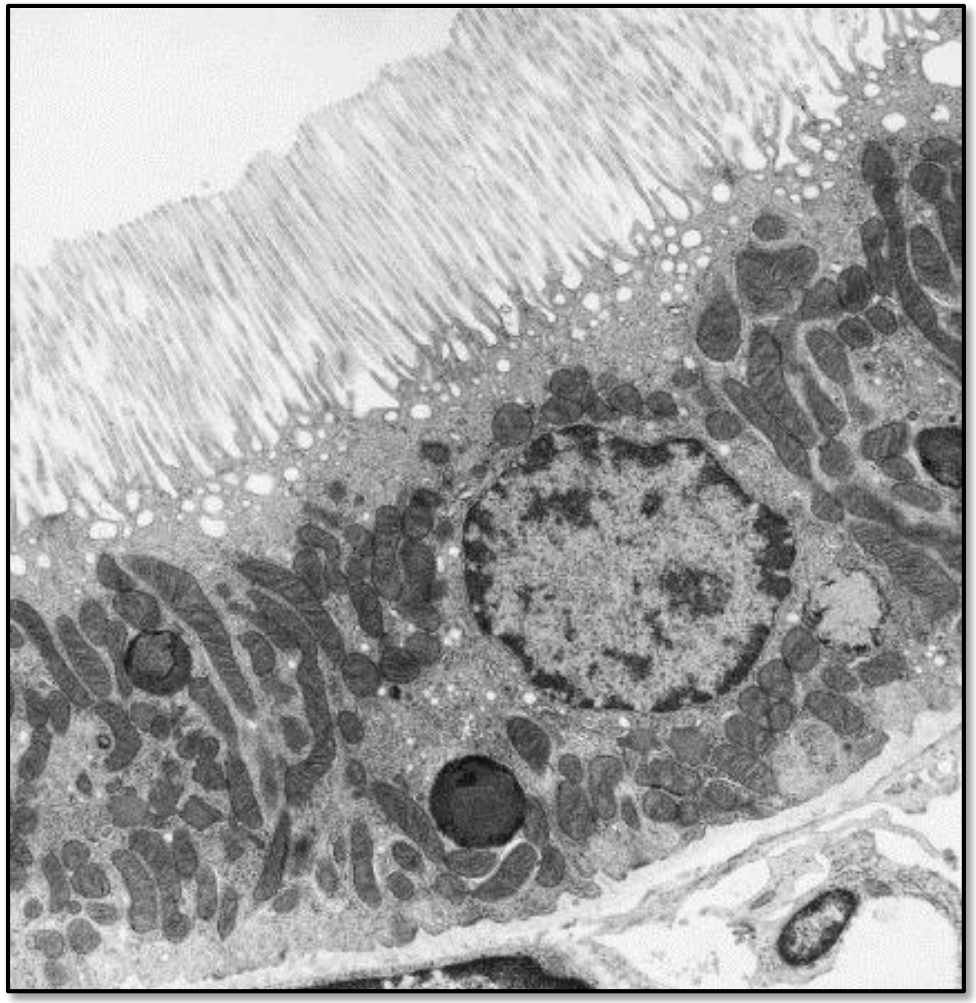

Autosomal dominant renal Fanconi syndrome

- Heterozygous missense mutation in the EHHADH gene
- Peroxisomal enzyme expressed in the proximal tubule involved in fatty acid oxidation
- The mutation introduces a new mitochondrial targeting motif
- Impaired mitochondrial oxidative phosphorylation with a dominant-negative effect

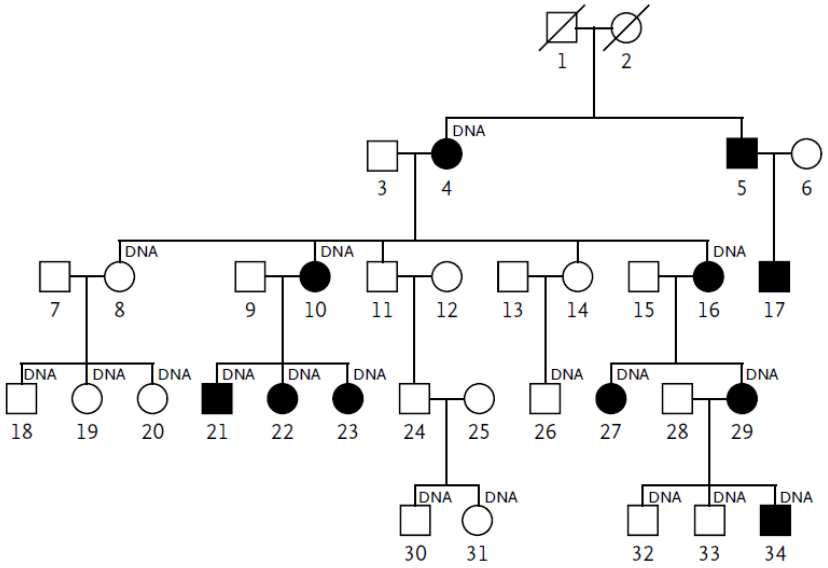

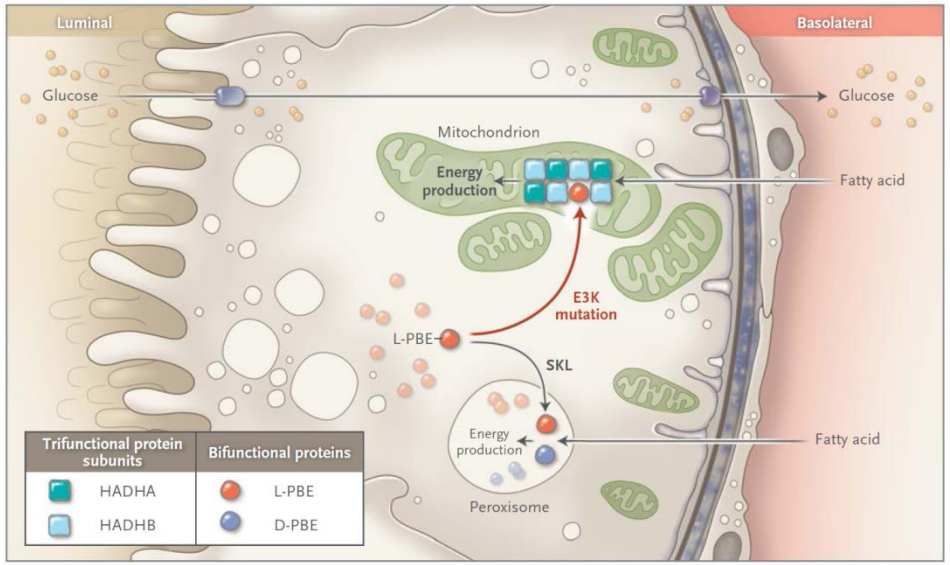

Klootwijk et al, NEJM 2014

Organic aciduria in renal mitochondrial disease

NB: may also be observed in the absence of hyperlactacidemia

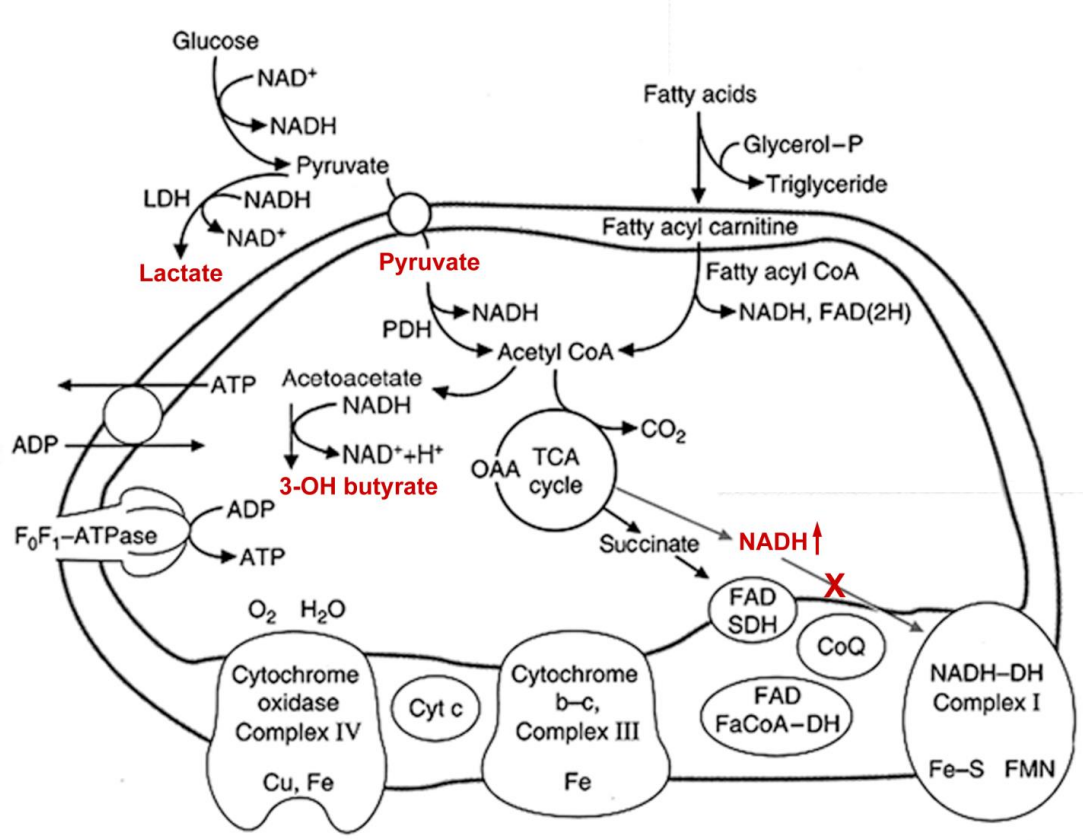

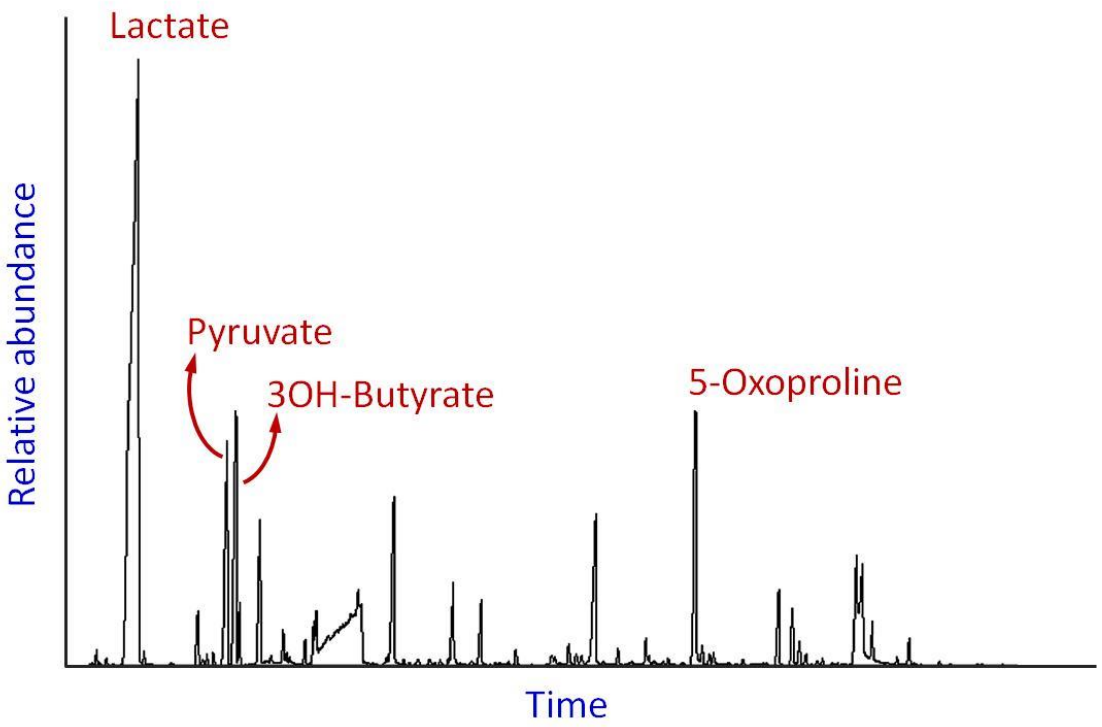

Electron microscopy in renal tubular mitochondrial diseases

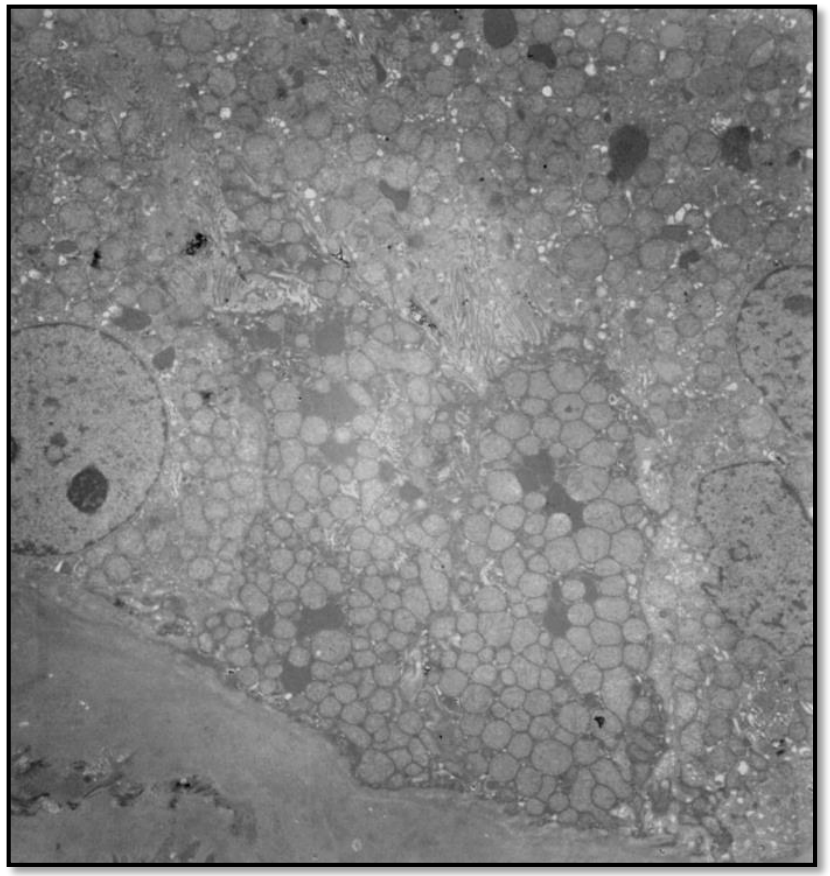

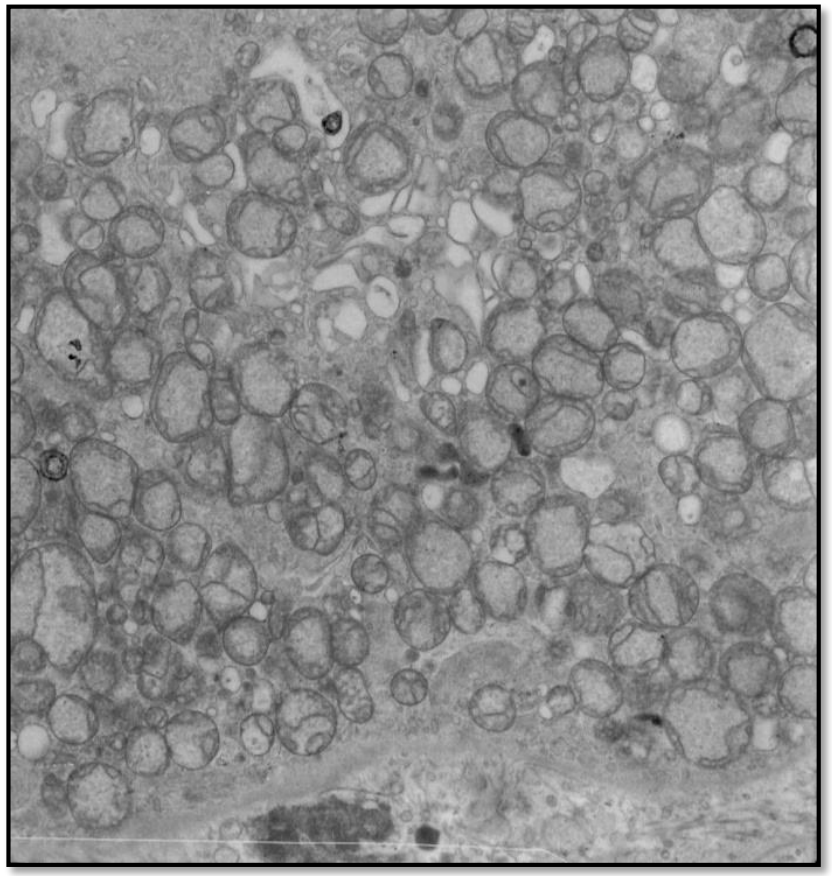

Hereditary tyrosinemia type I

- **Acute form (0-6 months)**
  most frequent
  hepatic and systemic failure

- **Sub-acute form (6-24 months)**
  hepatosplenomegaly
  coagulopathy
  failure to thrive
  Fanconi syndrome, often rickets
  neurologic crises (if untreated)

- **Chronic form (>2 years)**
  subclinical liver and/or renal tubular dysfunction

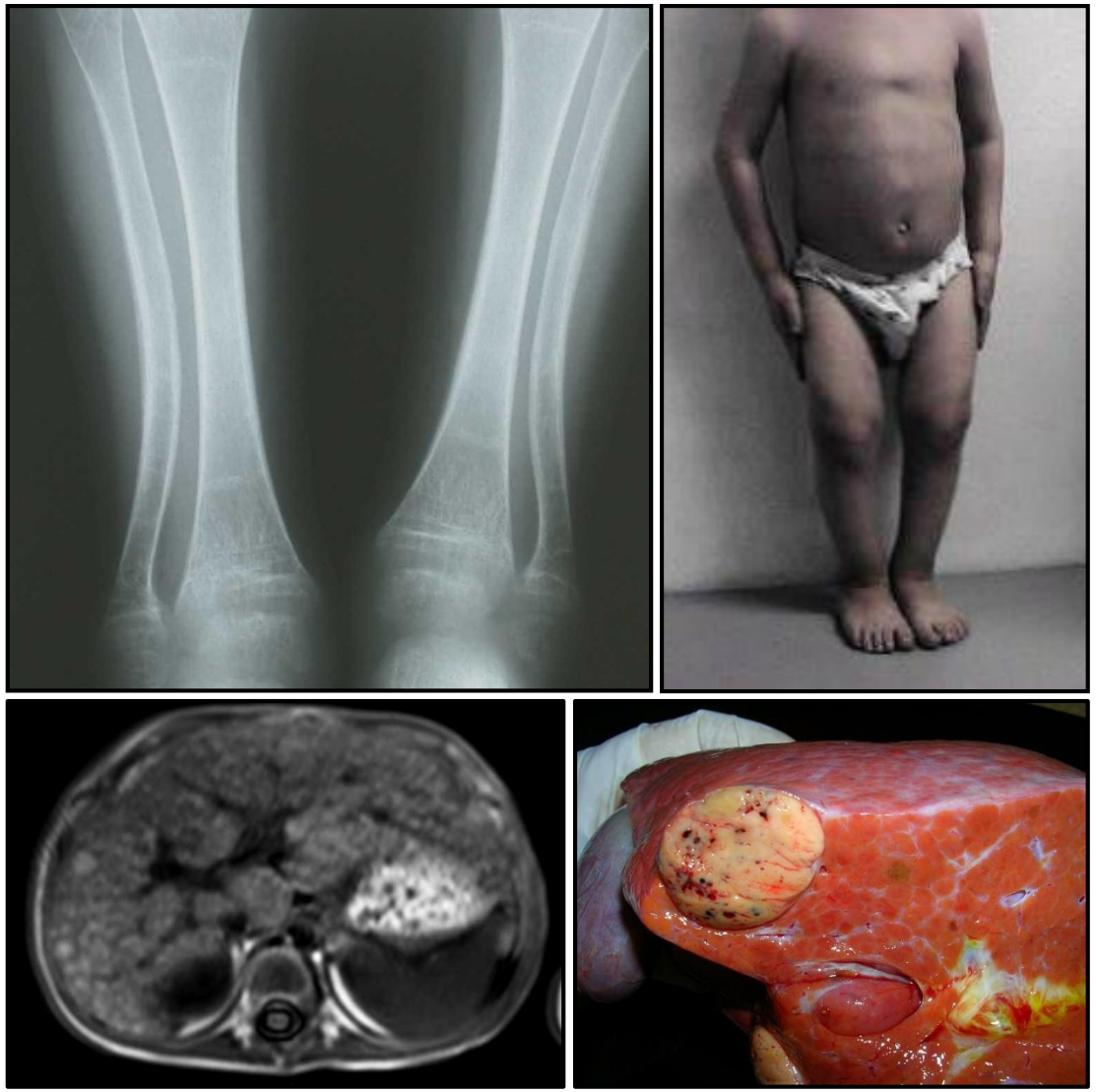

Hereditary tyrosinemia type I

- **Blood:**
  ↑↑↑ tyrosine, methionine, and phenylalanine
  ↑↑↑ alpha-fetoprotein
  NB: LFT's are often normal or only slightly elevated

- **Urine:**
  tyrosine metabolites
  (p-hydroxyphenylpyruvate, p-hydroxyphenyllactate, and p-hydroxyphenylacetate)

Toxic compounds in hereditary tyrosinemia type I

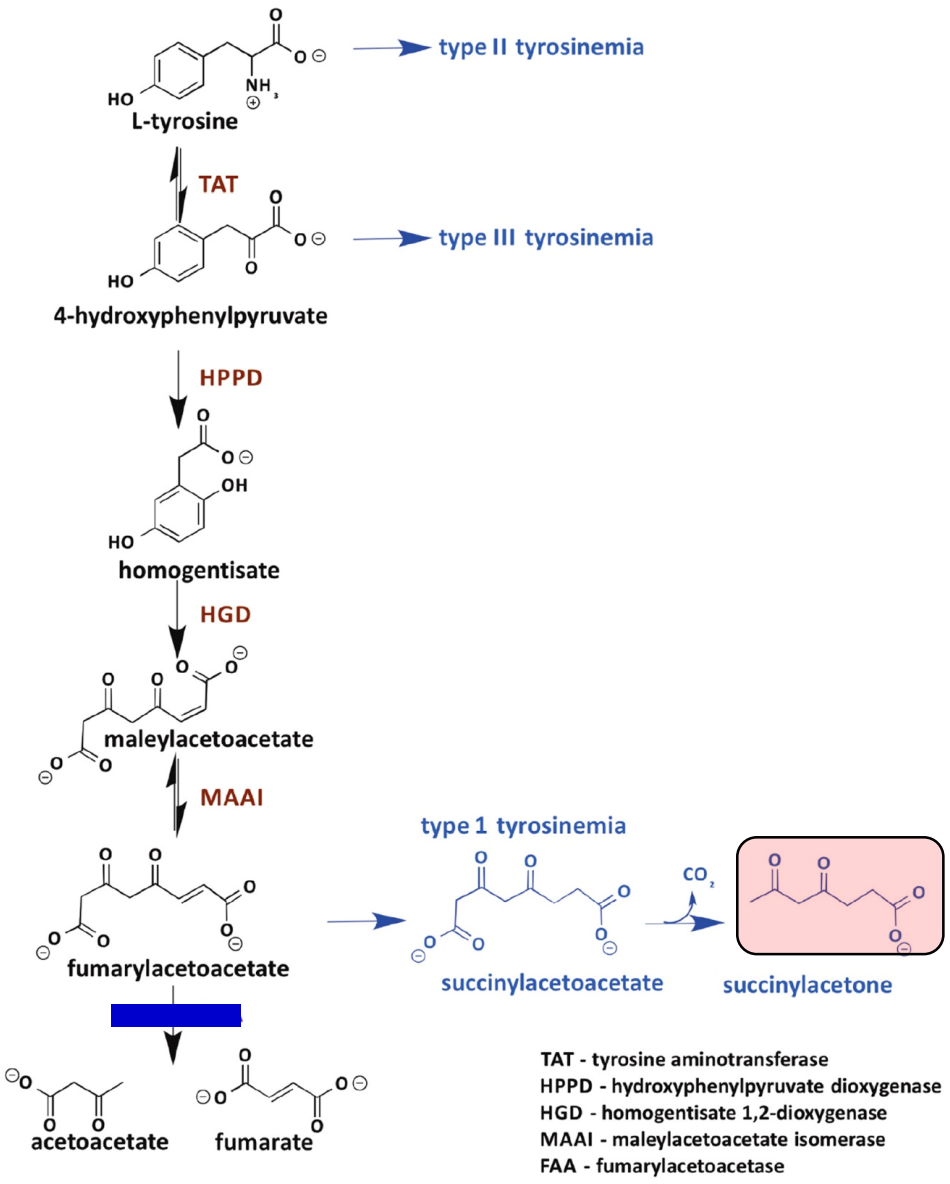



Lethal

Sun et al, JASN 2000

Toxic compounds in hereditary tyrosinemia type I

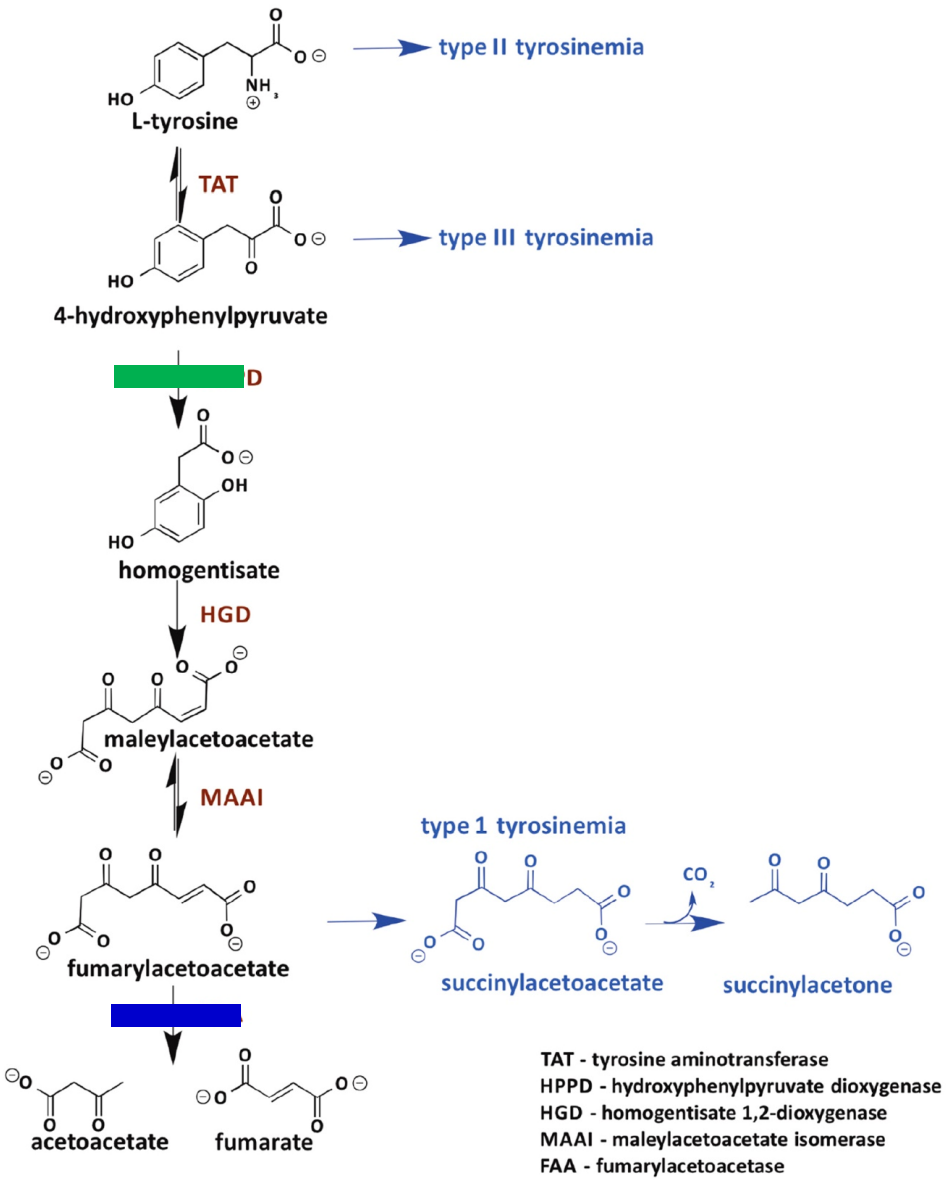



Lethal

No liver or renal disease

Sun et al, JASN 2000

Toxic compounds in hereditary tyrosinemia type I

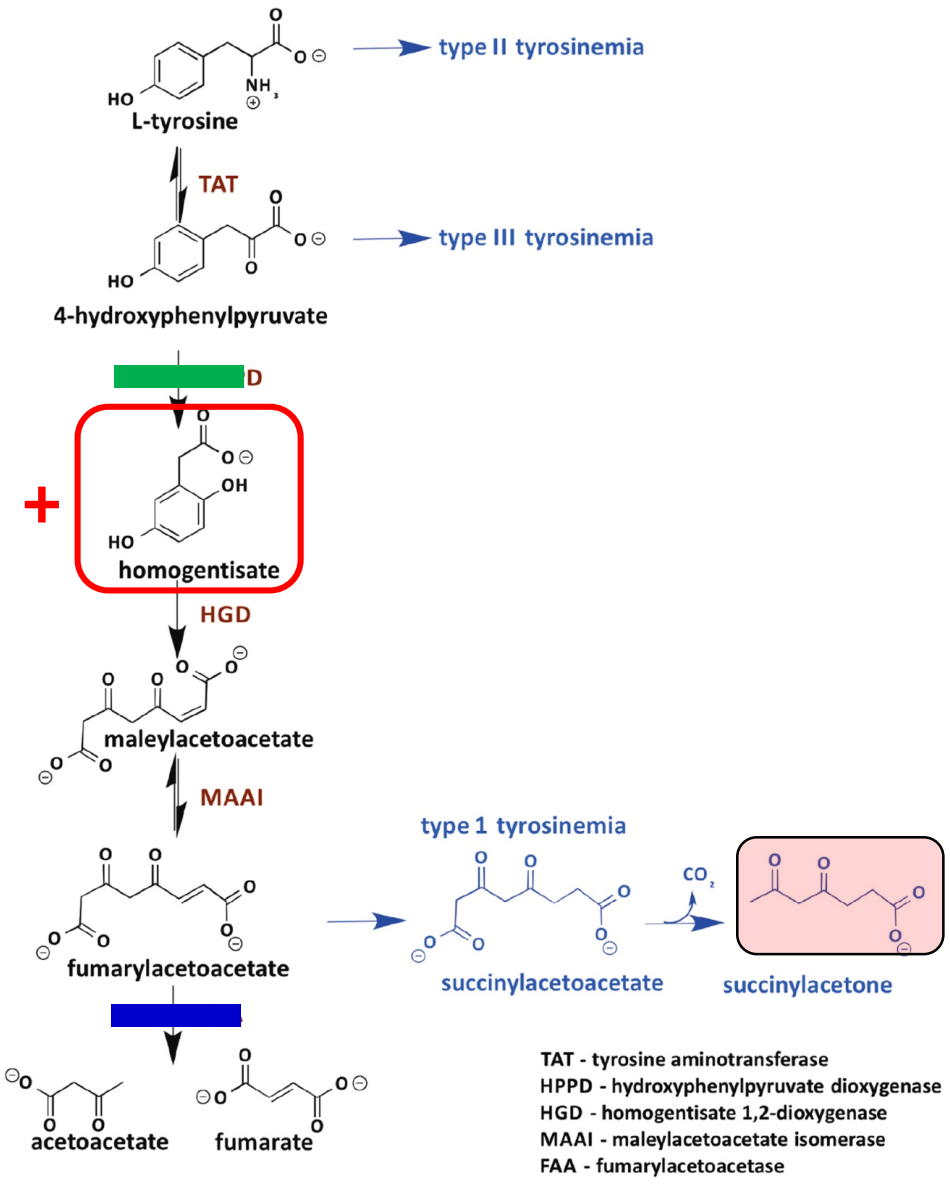



Lethal

No liver or renal disease

Fanconi syndrome

+ homogentisate

Sun et al, JASN 2000

Toxic effects of succinylacetone on renal tubular cells

- *In vitro*:
  1. direct inhibition of brush border transporters
  2. altered plasma membrane fluidity
  3. reduced O2 consumptions by tubular mitochondria (reversible)
  (Spencer Kidney International 1988)

- *In vivo* - experimental:
  injection in rats induces renal Fanconi syndrome
  (Spencer Biochem Med Metab Biol 1987)

- *In vivo* - humans:
  normalization of succinylacetone after liver transplantation corrects renal tubular acidosis
  (Herzog Transplantation 2006; Pierik JIMD 2005)

Toxic compounds in hereditary tyrosinemia type I

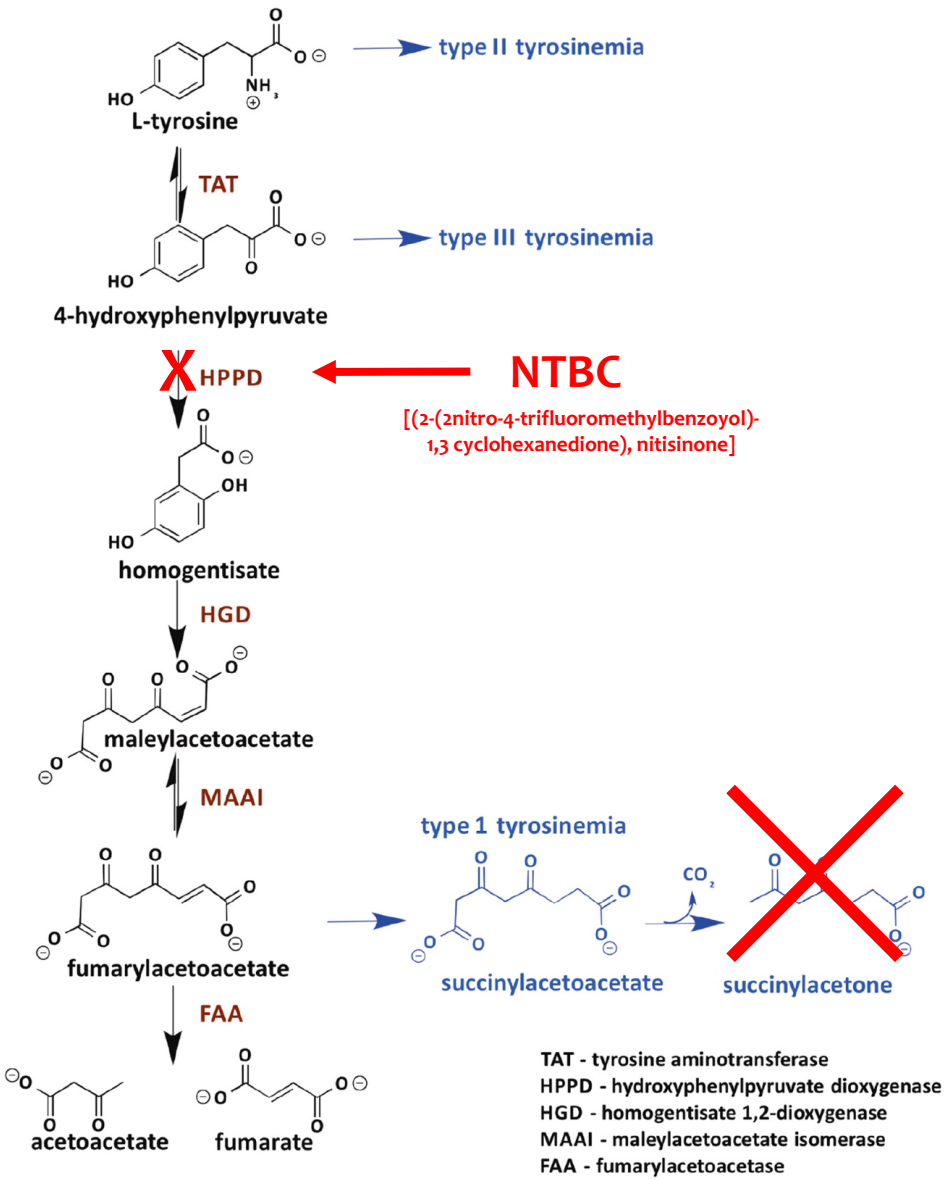

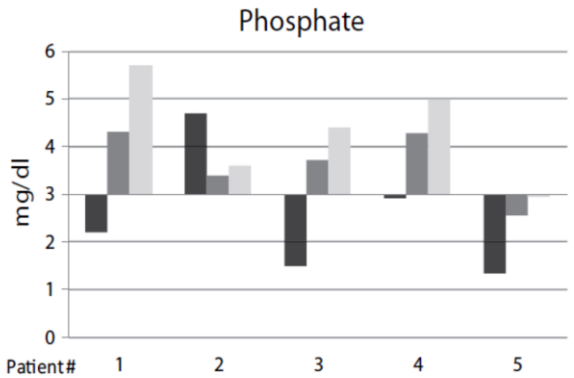

Patient n°5

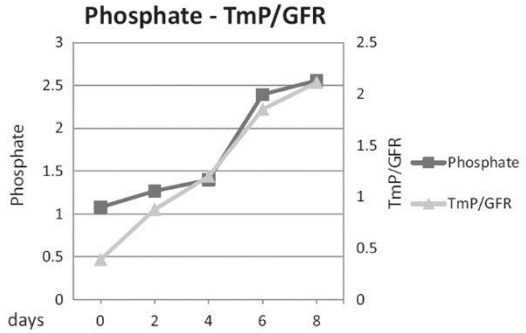

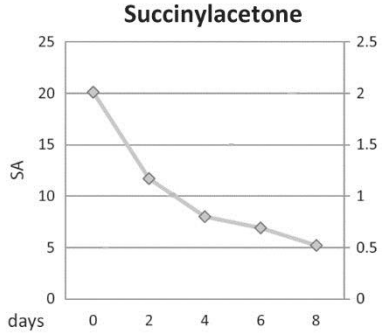

Maiorana et al, Mol Genet Metabol 2014

Receptor mediated endocytosis in proximal tubular cells

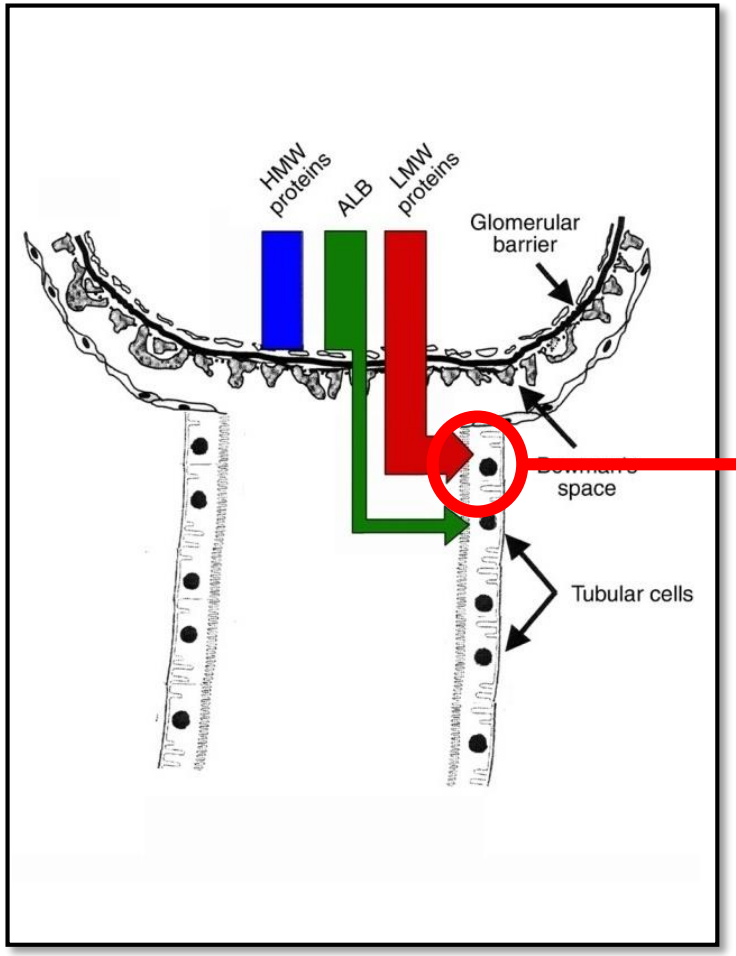

D'Amico, Kidney Int 2003

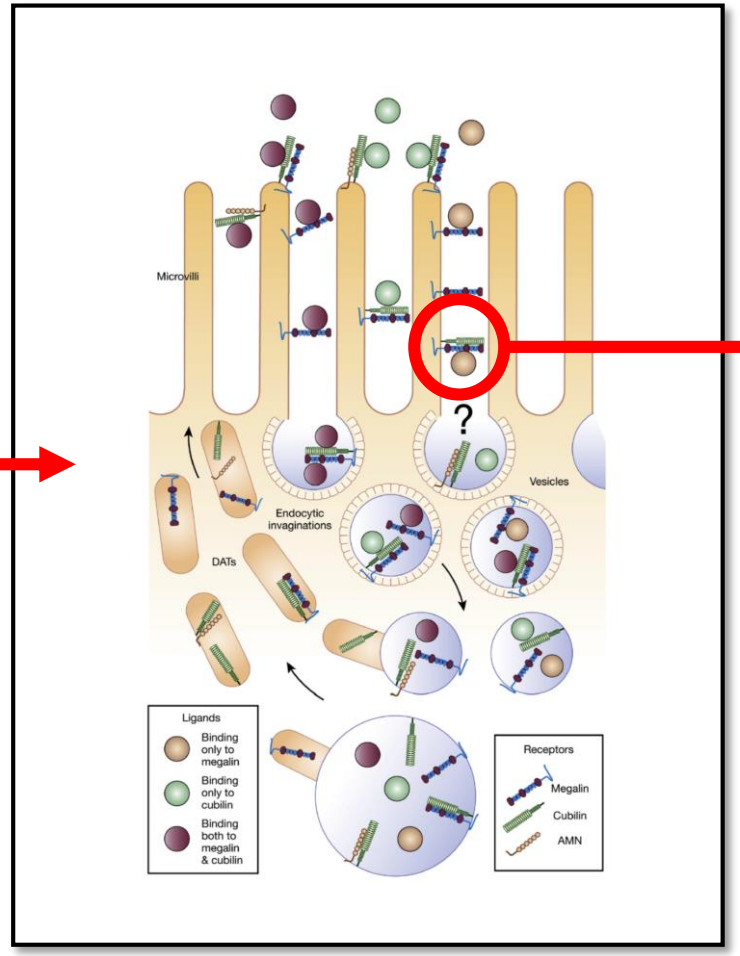

Nielsen et al, Kidney Int 2016

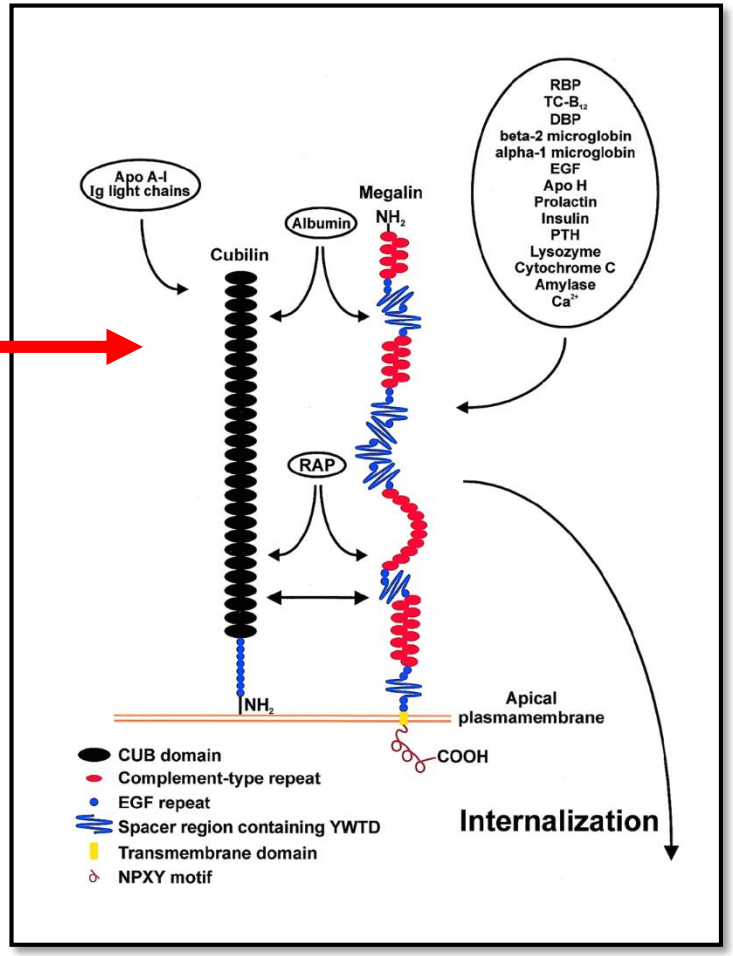

Christensen and Birn, Am J Physiol Renal 2001

Low molecular proteinuria

Carrier females of Dent's disease

AD Fanconi syndrome
Dent's disease
Lowe syndrome

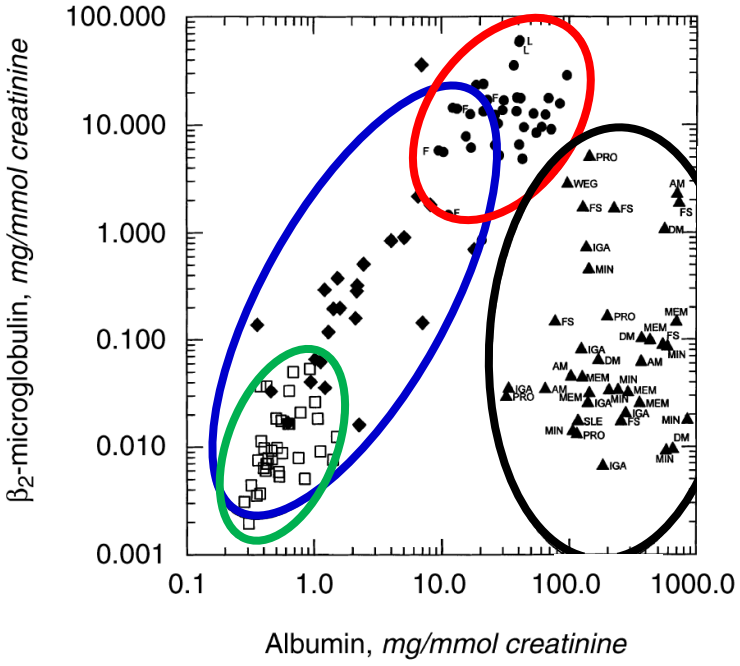

Normal subjects

Glomerulonephritis

Norden et al, Kidney Int., 2000

Genetic forms of Fanconi sindrome with overt low molecular proteinuria

DISEASE	LOCUS	PROTEIN
Cystinosis	CTNS	Cystinosin
Dent 1	CLCN5	CLC-5
Dent 2	OCRL1	PI-4,5-biphosphate-phosphatase
Lowe syndrome	OCRL1	PI-4,5-biphosphate-phosphatase
ARC syndrome	VPS33B, VIPAR	Vacuolar sorting proteins
Imerslund-Gräsbeck syndrome	CUBN, AMN	Cubilin, Amnionless
Donnai-Barrow syndrome	LRP2	Megalin
Severe PTC cytopathies	~	~
Idiopathic Fanconi Syndrome	?	?

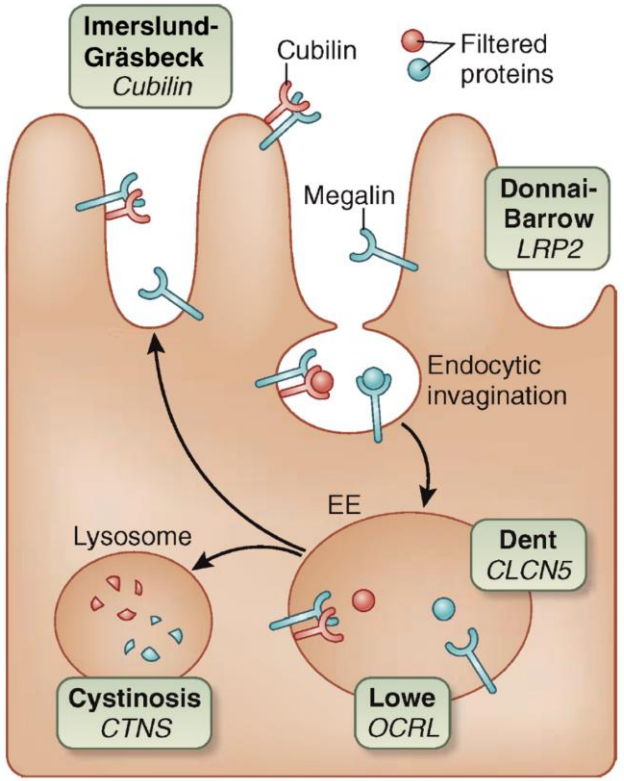

Willow et al, Kidney Int 2017

Imerslund-Gräsbeck syndrome

- Selective Vit. B12 malabsorption with LMWP
- AR disorder, first described in Finland and Norway (prevalence 1:200,000)
- Megaloblastic anemia, responsive to parenteral Vit. B12 therapy
- Other reported manifestations (infrequent):
  - failure to thrive
  - frequent infections
  - neurological symptoms

Mutations in the CUBN or AMN genes

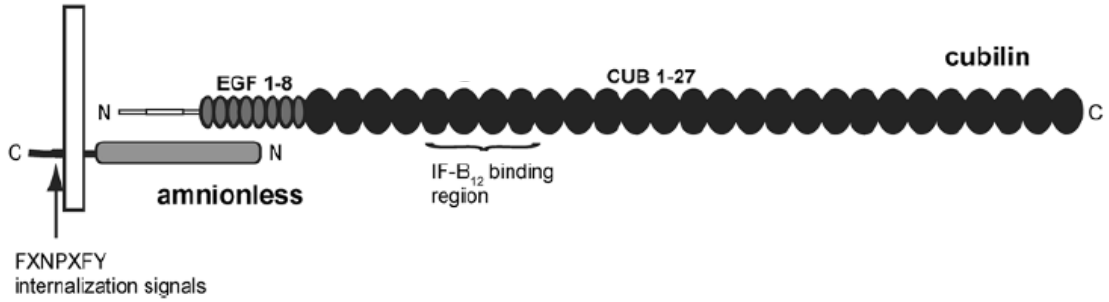

amnionless is required for the expression of cubilin in the brush-border

Storm et al. BMC Medical Genetics 2013

Intestinal receptor for the Vit B12 - intrinsic factor complex

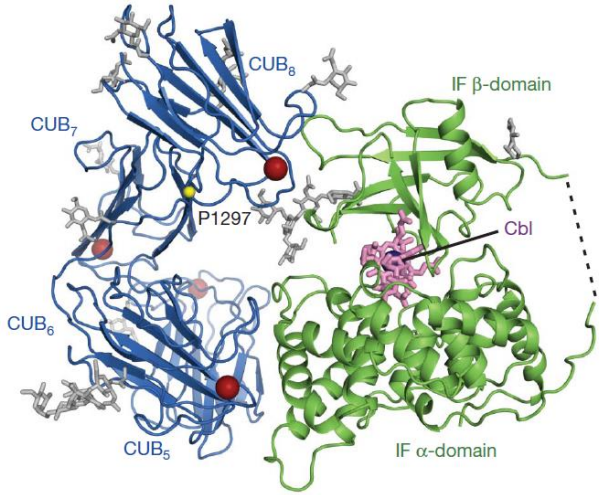

Andersen et , Nature 2010

Imerslund-Gräsbeck syndrome: CUBN mutation

- 20 year old male born from consanguineous parents
- At 17 months: anorexia and megaloblastic anemia (Hb 5.3 g/dl; MCV 97 fl)
- Homozygous CUBN exon 23 (c.3329+1G>T)
- Renal biopsy for IgA nephropathy

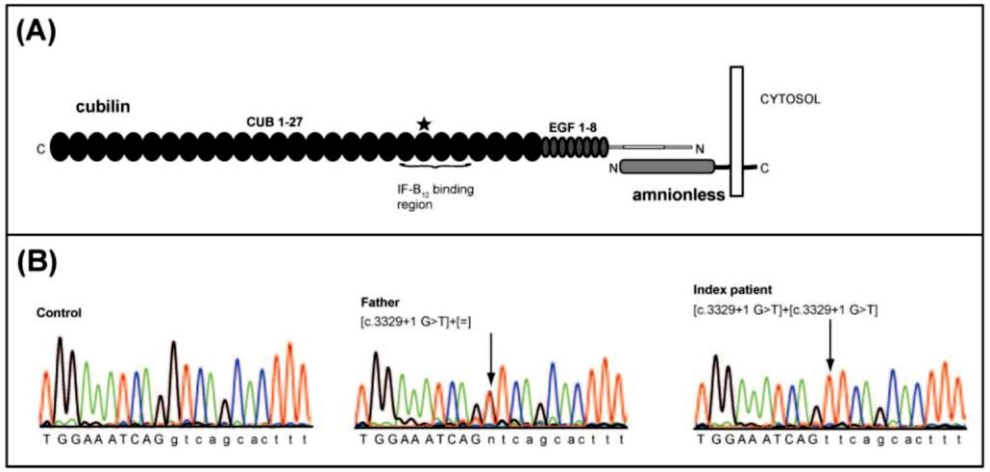

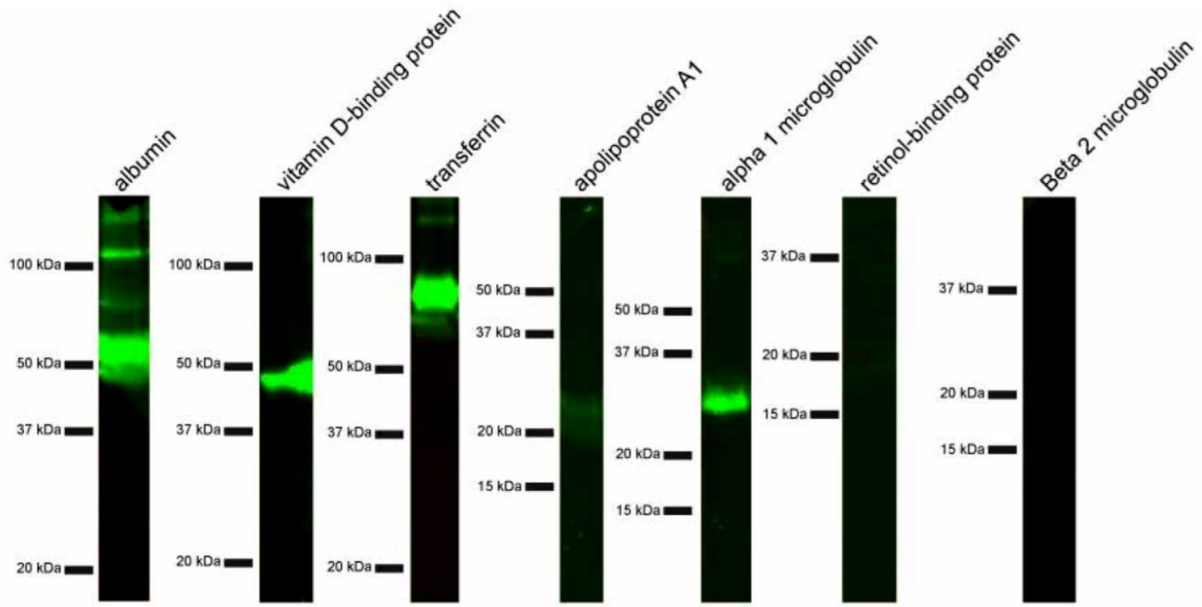

Storm et al, NEJM 2011

Imerslund-Gräsbeck syndrome: CUBN mutation

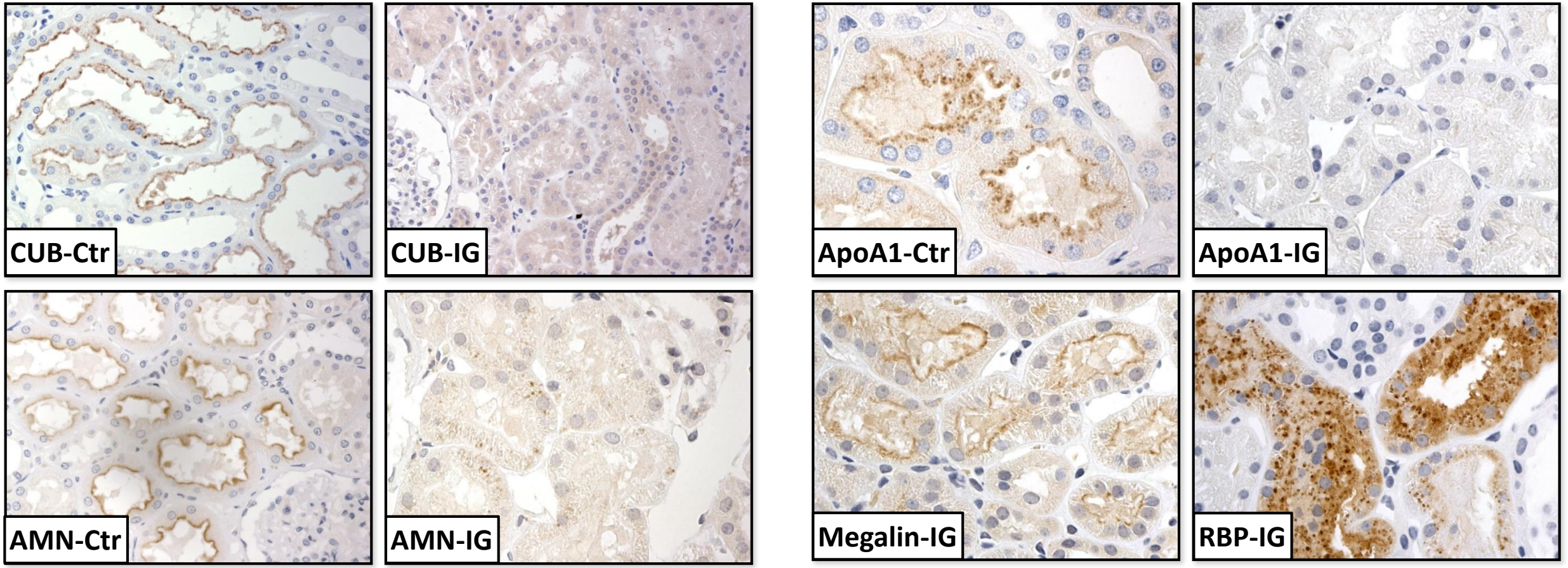

Storm et al, NEJM 2011

Donnai-Barrow syndrome (facio-oculo-acustico-renal syndrome)

- **Face:**
  wide-set eyes - outer corners pointing downward
  short bulbous nose - flat nasal bridge
  back-rotated ears
  widow's peak hairline

- **Eye:**
  severe myopia
  retinal detachment
  iris coloboma

- **Ear:**
  sensorineural hearing loss

- **Kidneys:**
  low molecular weight proteinuria
  FSGS?

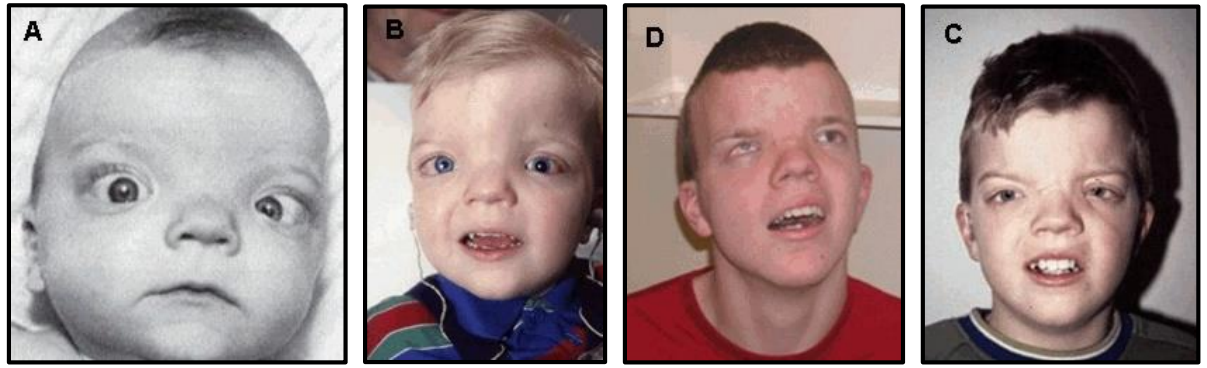

Kantarci S, Donnai D, Noonan KM, et al. GeneReviews®

- **Other features:**
  ipoplasia of the *corpus callosum*
  mild to moderate intellectual disability
  congenital diaphragmatic hernia
  omphalocele

- **Very rare**

- **LRP2 gene mutations**

Megalin and cubilin expression in genetic and acquired PT diseases

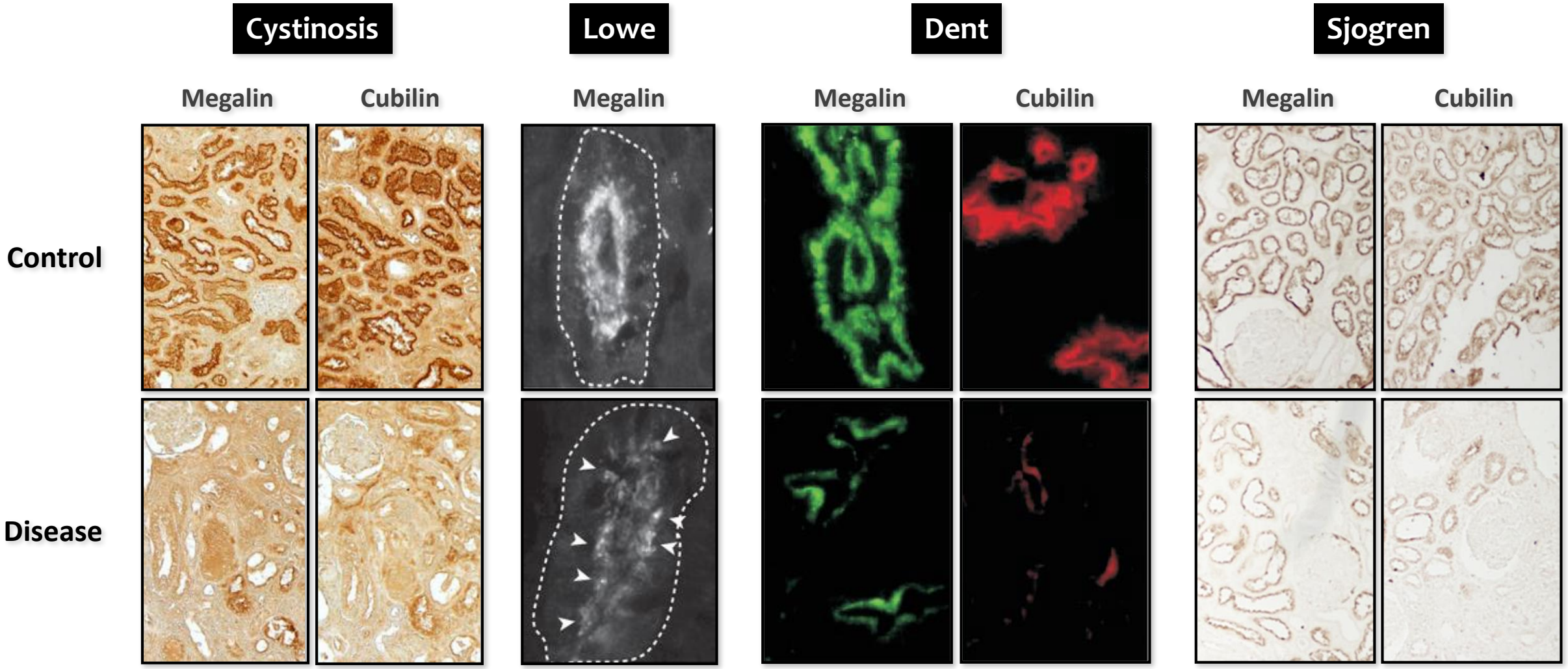

Human
Gaide Chevronnay et al, JASN 2014

Zebrafish
Otrabella et al, Plos Genet 2015

Mouse
Christensen et al, PNAS 2003

Human
Wang et al, Arthritis Res Ther 2017

Overlapping phenotypes between Dent disease and Lowe syndrome

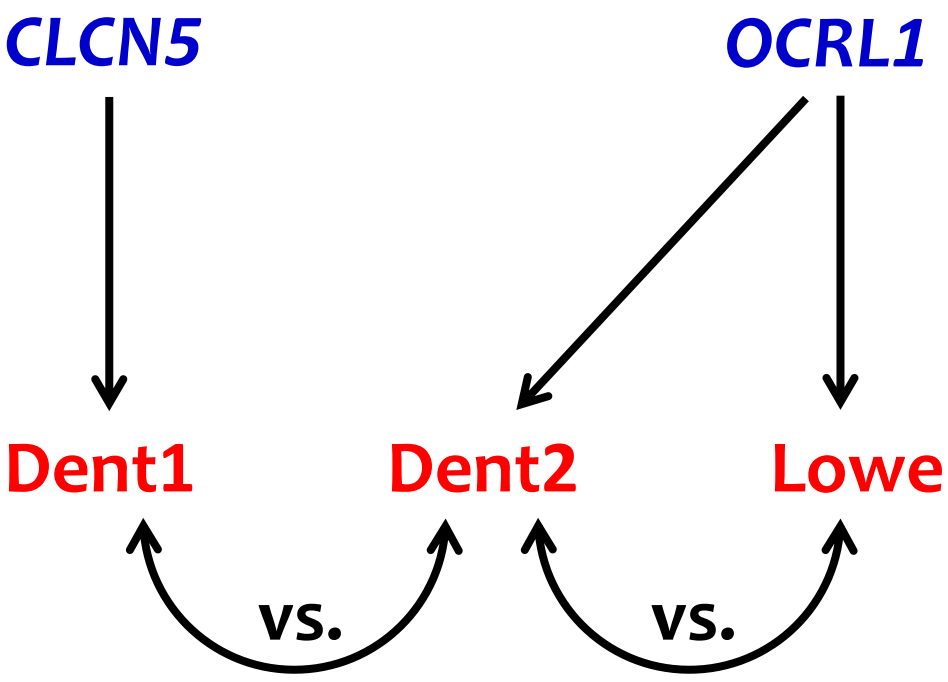

Dent 1 vs. Dent 2

Table 1 | Presentation at clinical diagnosis of patients with Dent type 1 and type 2

	Dent-1 ($n = 108$)	Dent-2 ($n = 9$)
Age at diagnosis[a]	11 (5–21)	6 (3–8)
LMWP	93 of 93 (100%)	7 of 7 (100%)
Hypercalciuria	81 of 88 (92%)	3 of 3 (100%)
Nephrolithiasis	24 of 74 (32%)	1 of 6 (17%)
● Nephrocalcinosis	44 of 104 (42%)	1 of 9 (11%)
Aminoaciduria	16 of 32 (50%)	4 of 5 (80%)
● Renal hypouricemia	19 of 30 (63%)	1 of 1 (100%)
Hypokalemia	31 of 70 (44%)	1 of 4 (25%)
● Glycosuria	26 of 58 (45%)	0 of 6 (0%)
Acidosis	9 of 54 (17%)	2 of 8 (25%)
Incomplete Fanconi syndrome[b]	51 of 70 (73%)	5 of 9 (55%)
Complete Fanconi syndrome[c]	8 of 70 (11%)	1 of 9 (11%)
Rickets	14 of 75 (19%)	1 of 7 (14%)
● Failure to thrive	12 of 40 (30%)	4 of 6 (67%)

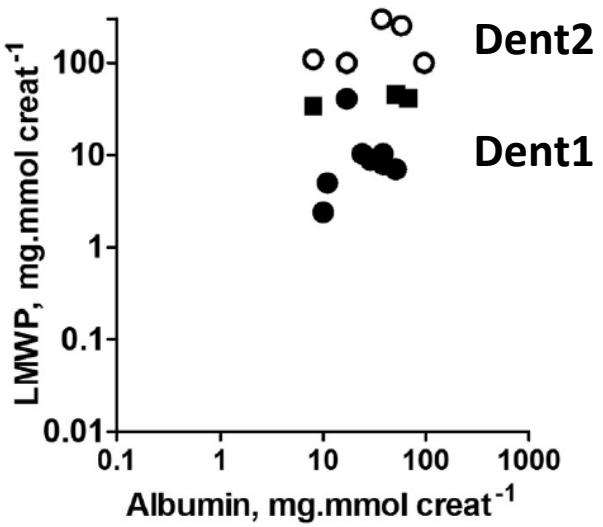

+ urinary concentration defect

+ increased LDH and CPK in Dent 2

Blanchard et al, Kidney Int 2016

Chronic renal failure: Dent 1 vs. Dent 2 vs. Lowe

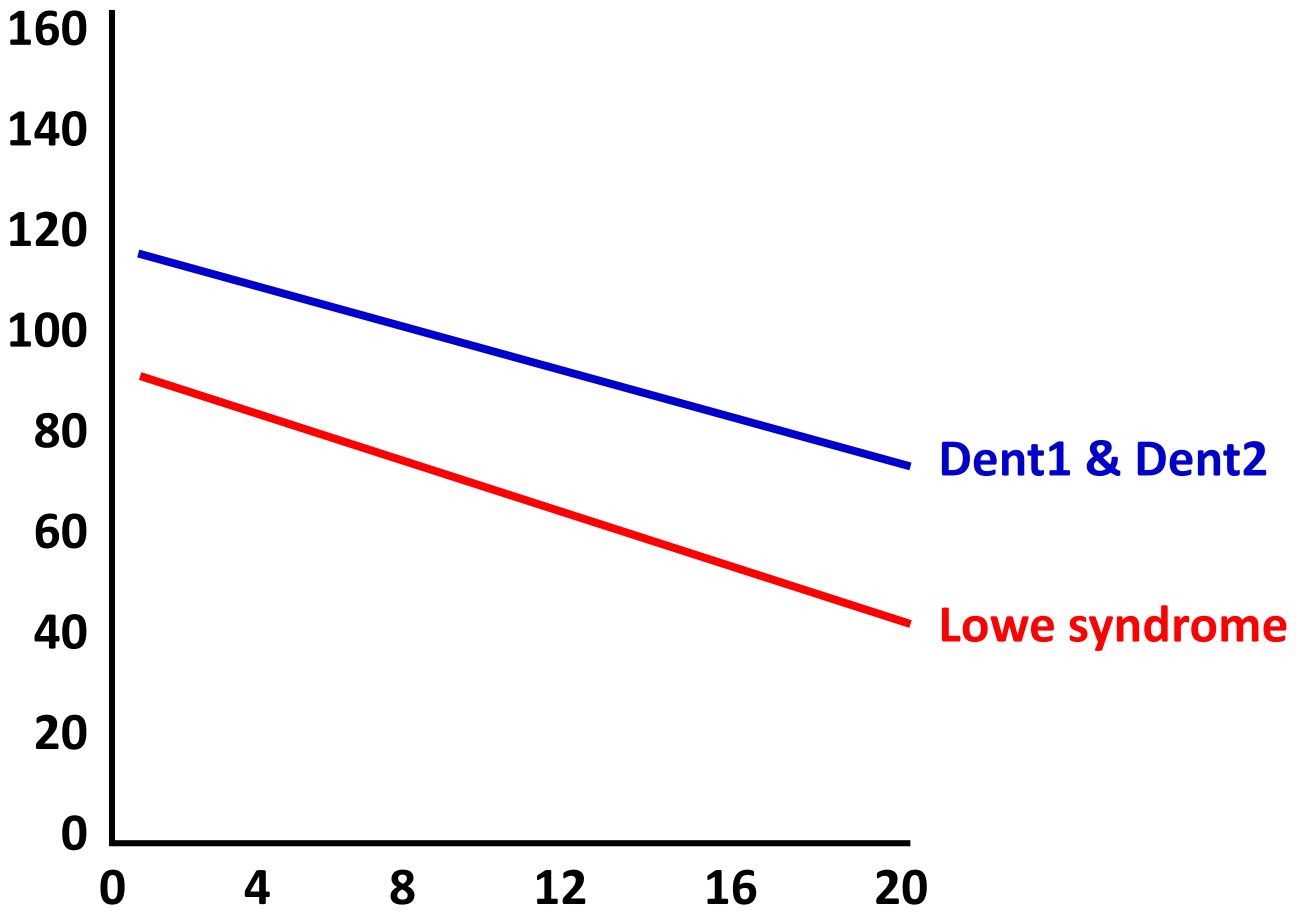

Data extrapolated from Blanchard et al, Kidney Int 2016 and from Zaniew et al, Nephrol Dial Transpl 2016

Dent 2 vs. Lowe

Table 1 | **Frequency* of renal and extrarenal abnormalities**

Abnormality	Lowe	Dent disease 2
Extrarenal		
Cataract‡	100%	7%
Intellectual impairment§	100%	27%
Growth retardation (mean height SDS)	100% (−3,7)	Frequent (−2,1)
Arthropathy‖	Frequent	Infrequent
Elevated CPK and /or LDH¶	98%	97%
Renal		
Nephrocalcinosis	45%	28%
LMWP	100%	100%
Albuminuria#	100%	NA
Lysosomal enzymuria	100%	NA
Aminoaciduria	79%	41%
Hypercalciuria	82%	78%
Metabolic acidosis	57%	4%
Phosphate wasting	51%	15%
Potassium wasting	23%	4%
Glycosuria	10%	15%

De Matteis et al, Nat Rev Nephrol 2017

Mutations in Lowe syndrome and Dent 2 disease

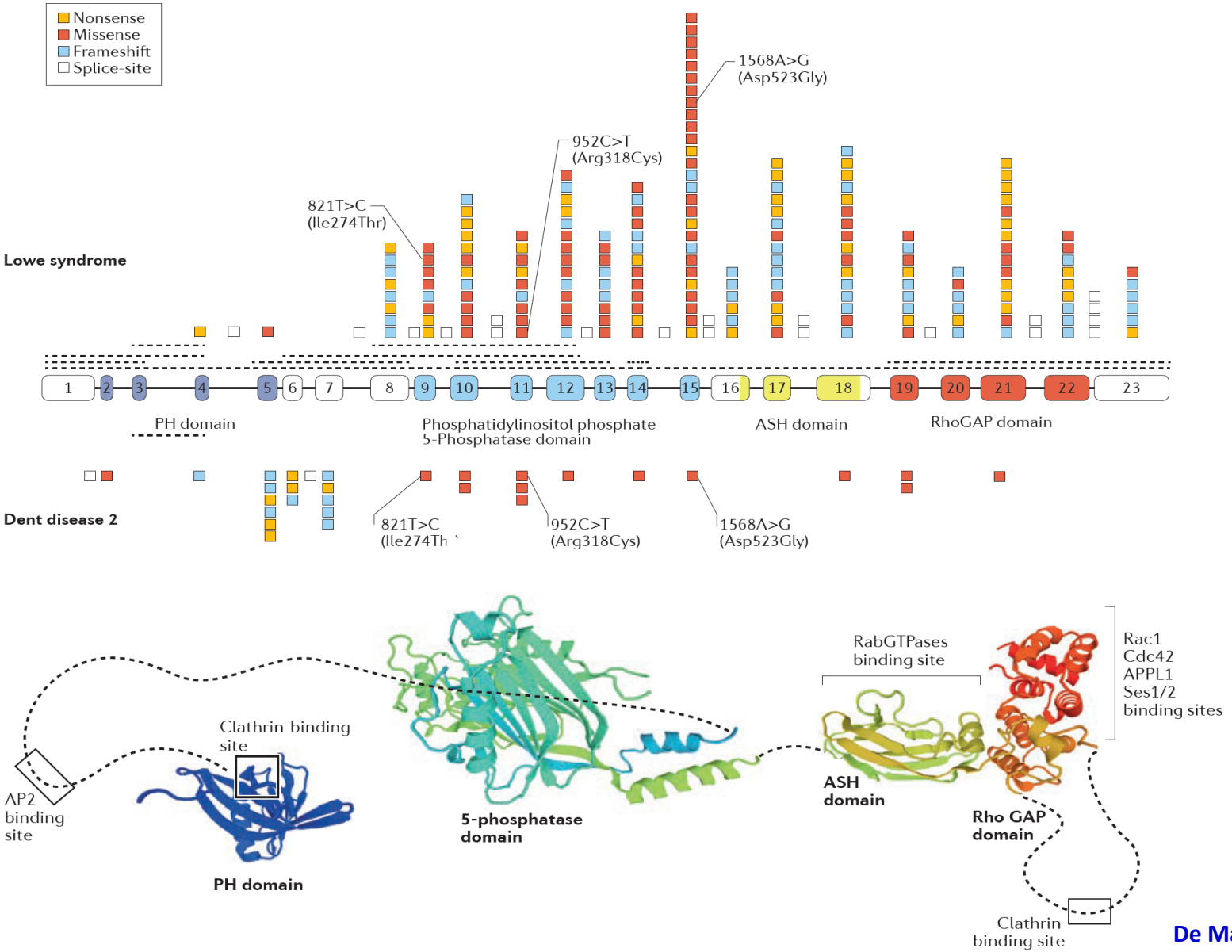

De Matteis et al, Nat Rev Nephrol 2017

Thank you

francesco.emma@opbg.net