ERKNet

The European Rare Kidney Disease Reference Network

NHS
Manchester University
NHS Foundation Trust

MANCHESTER 1824
The University of Manchester

Persistent Glomerular Microscopic Haematuria

Rachel Lennon
Professor of Nephrology & Consultant Paediatric Nephrologist,
Wellcome Trust Senior Research Fellow in Clinical Science,
University of Manchester

ERKNet Webinar: Nov 06, 4 pm (CET)

Overview

- Differential diagnosis
- Familial haematuria
- Alport syndrome
  - Phenotypic variation
- Heterozygous mutations in *COL4A3, COL4A4*
- Intervention
- Summary

Causes of haematuria in children

MANCHESTER 1824
The University of Manchester

- Glomerular
  - Glomerulonephritis
    - C3 deposition
    - IgA disease (Henoch-Schönlein Pupura)
  - **Basement membrane glomerulopathy**
- Non-glomerular
  - Infection, hypercalciuria, renal stone disease, polycystic kidneys, tumours, arteriovenous malformation, loin-pain-haematuria syndrome, fabricated/induced illness
- 1% general population, 30-50% familial condition

Investigations

- Urine:
  - Microscopy- confirm red cells
  - Calcium: creatinine ratio
- Haematology:
  - FBC, coagulation
- Biochemistry:
  - Renal profile:
    - (urea, electrolytes, creatinine, albumin, calcium, phosphate, bicarbonate, uric acid)
- Immunology:
  - ASO titre, C3/C4, anti-nuclear antibodies
- Radiology:
  - Renal consider USS/XRay (KUB)
- Genetics…

The Glomerular Filtration Barrier

MANCHESTER 1824
The University of Manchester

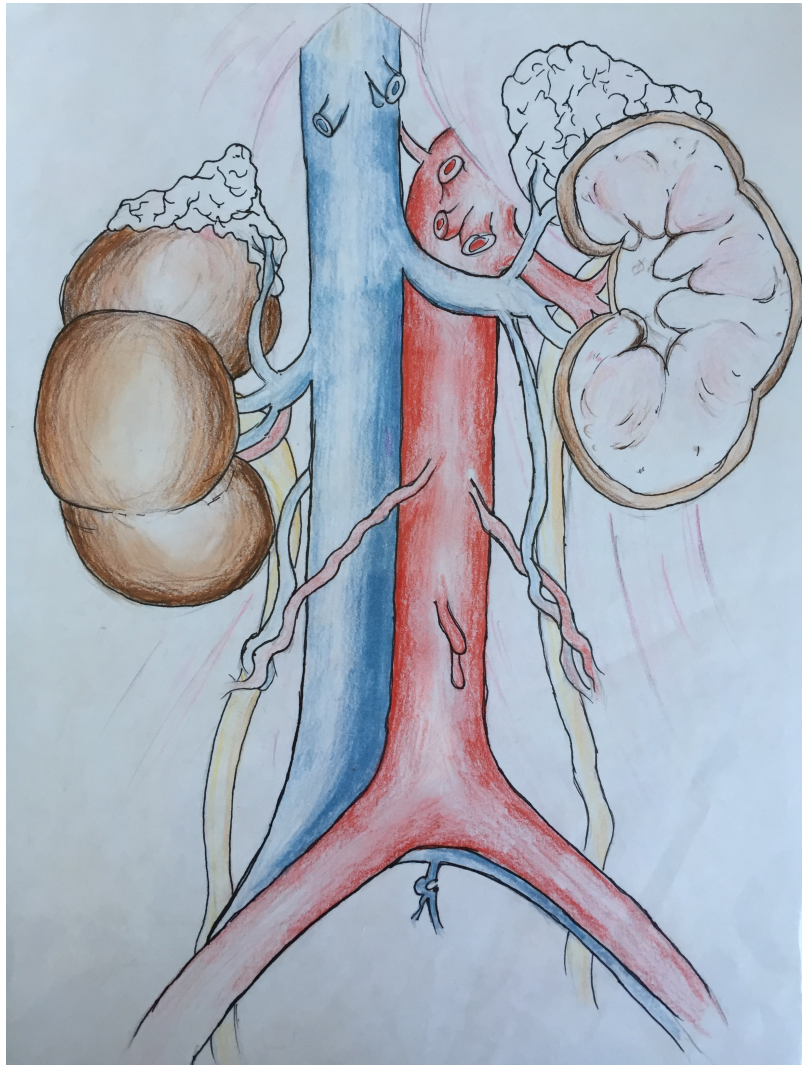

Mammalian, metanephric kidneys

~1 million nephrons in each kidney

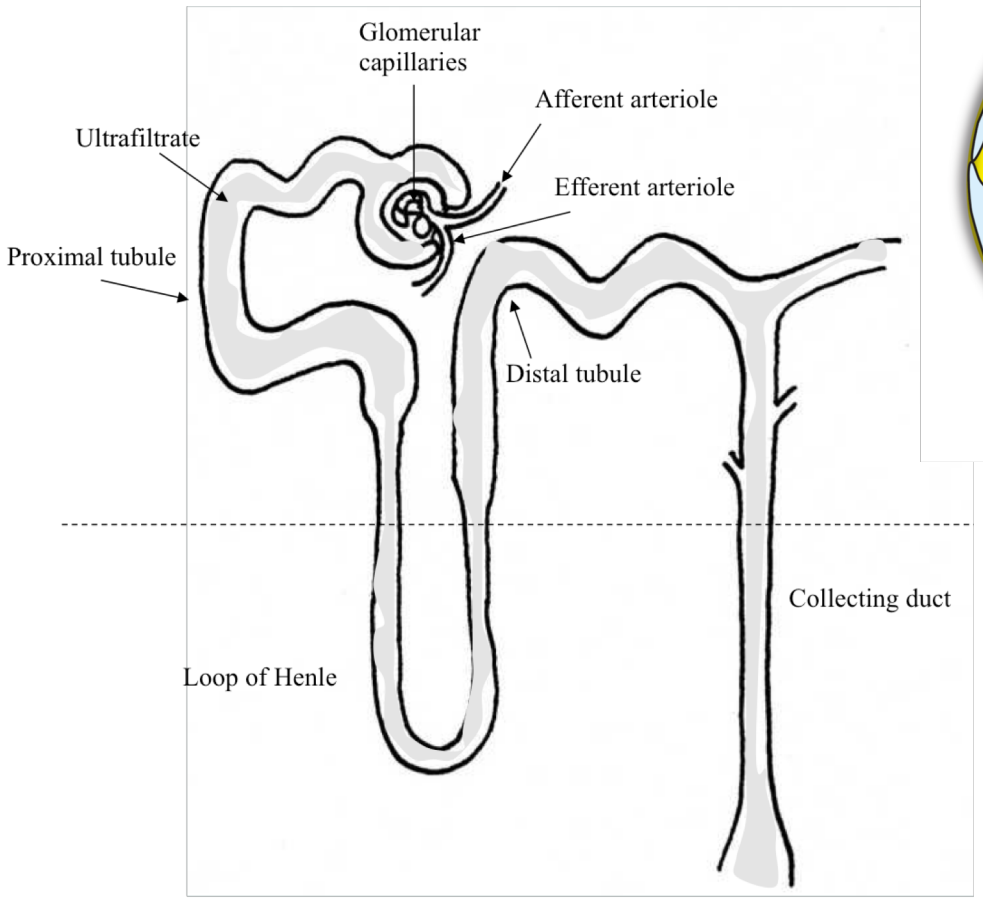

The glomerulus or 'filter'

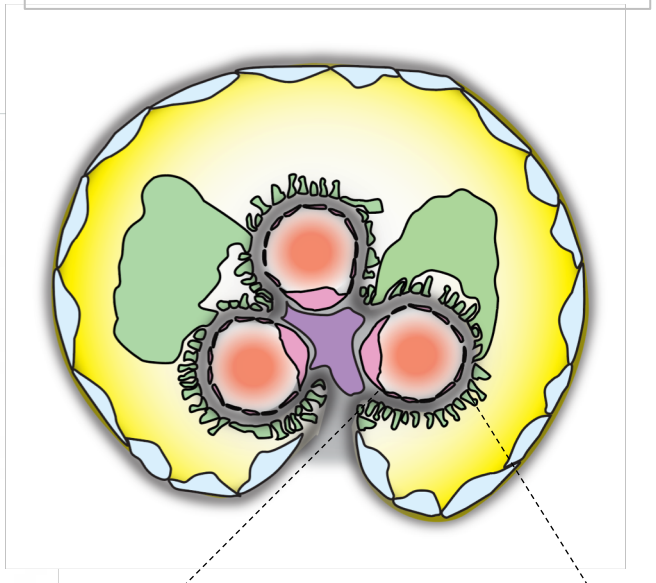

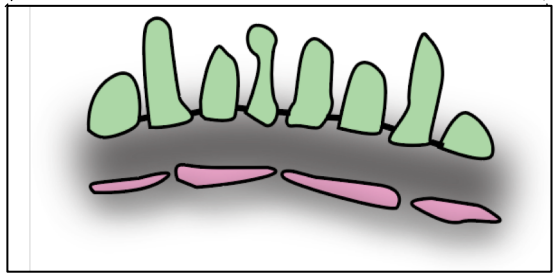

The filtration barrier

A specialised capillary wall

MANCHESTER 1824
The University of Manchester

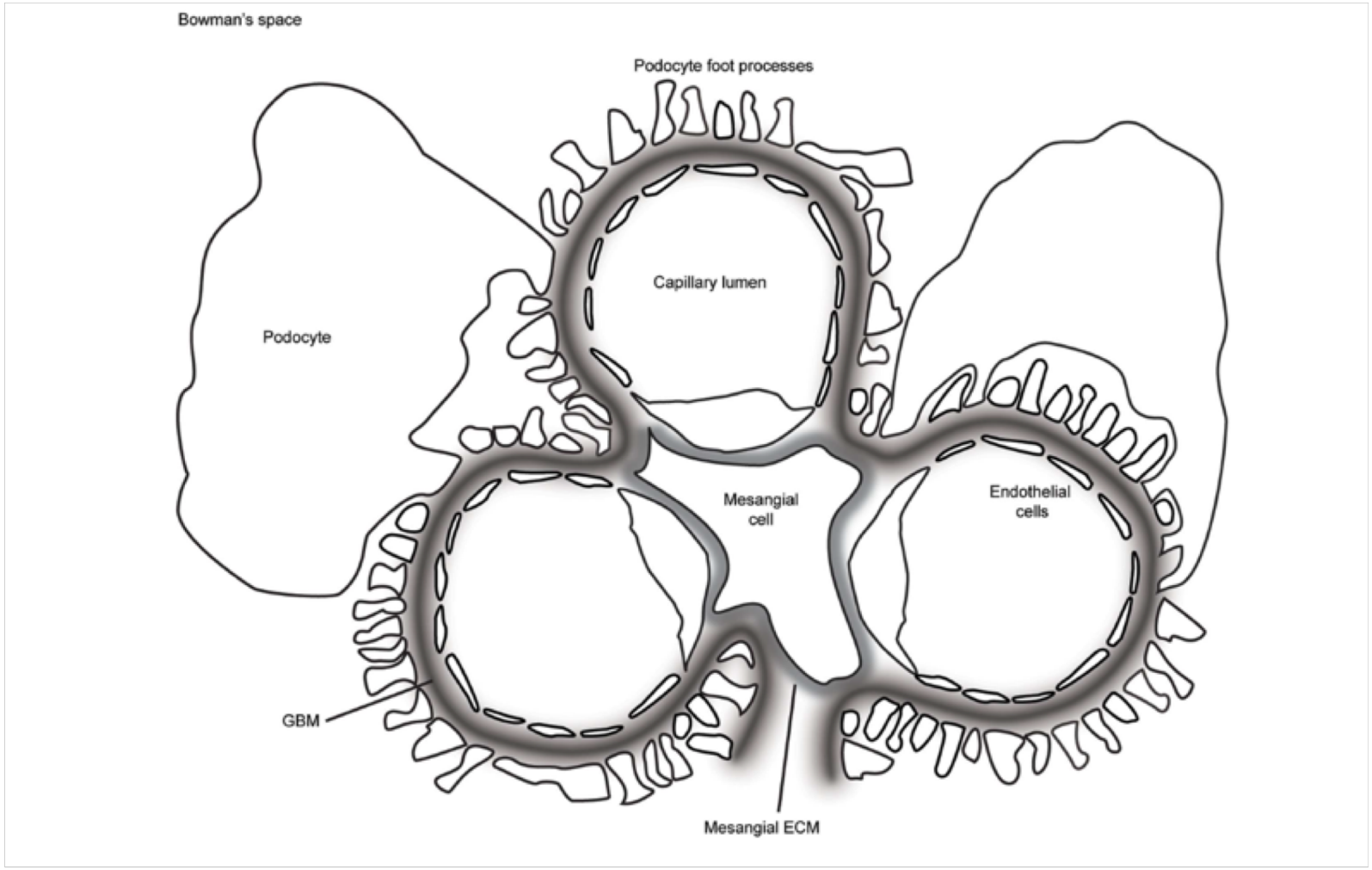

Lennon R, Randles MJ, Humphries MJ:
The Importance of Podocyte Adhesion for a Healthy Glomerulus. *Frontiers 2014*

Barrier breakdown

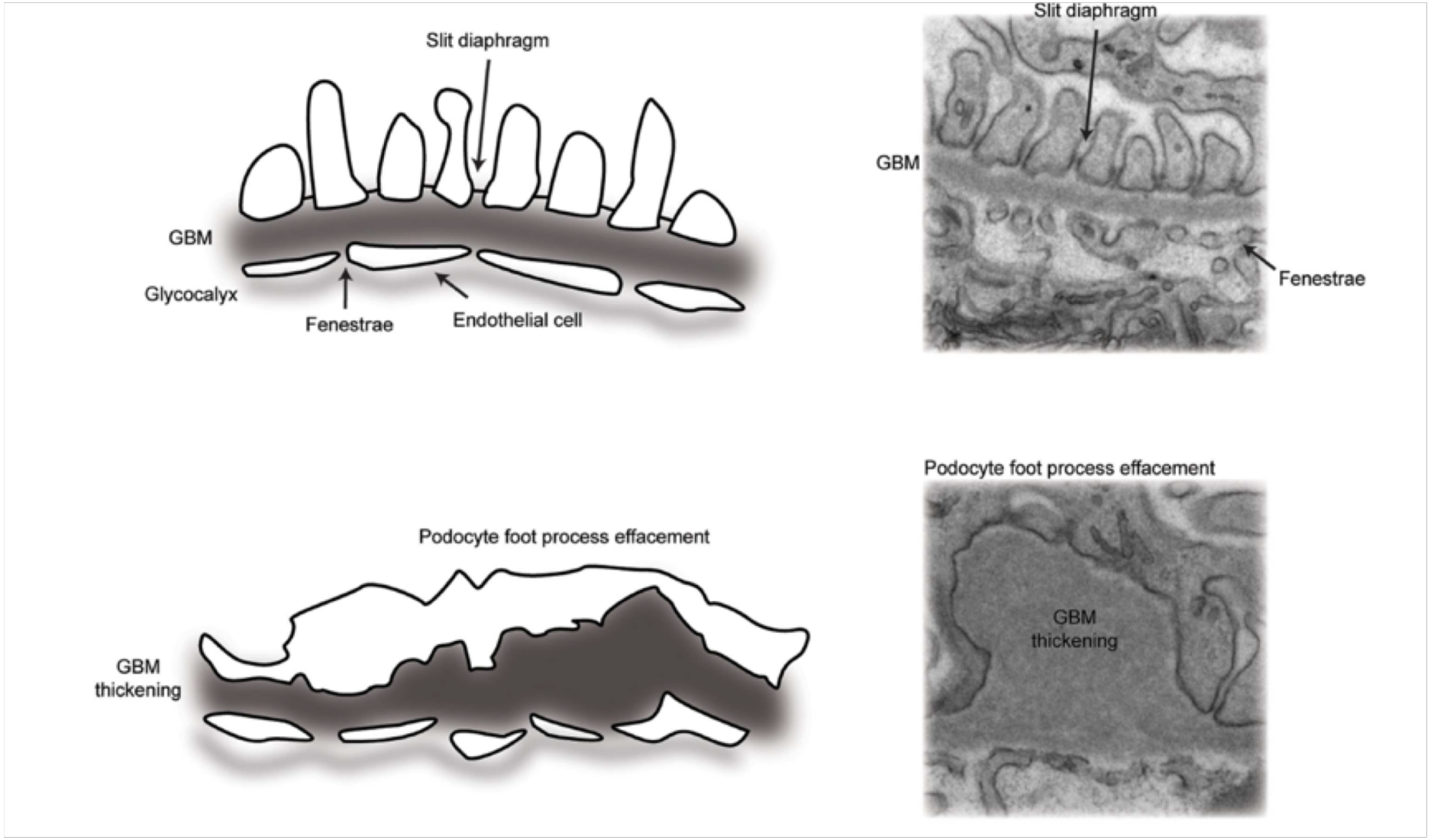

Collagen IV- *the smart scaffold*

MANCHESTER 1824
The University of Manchester

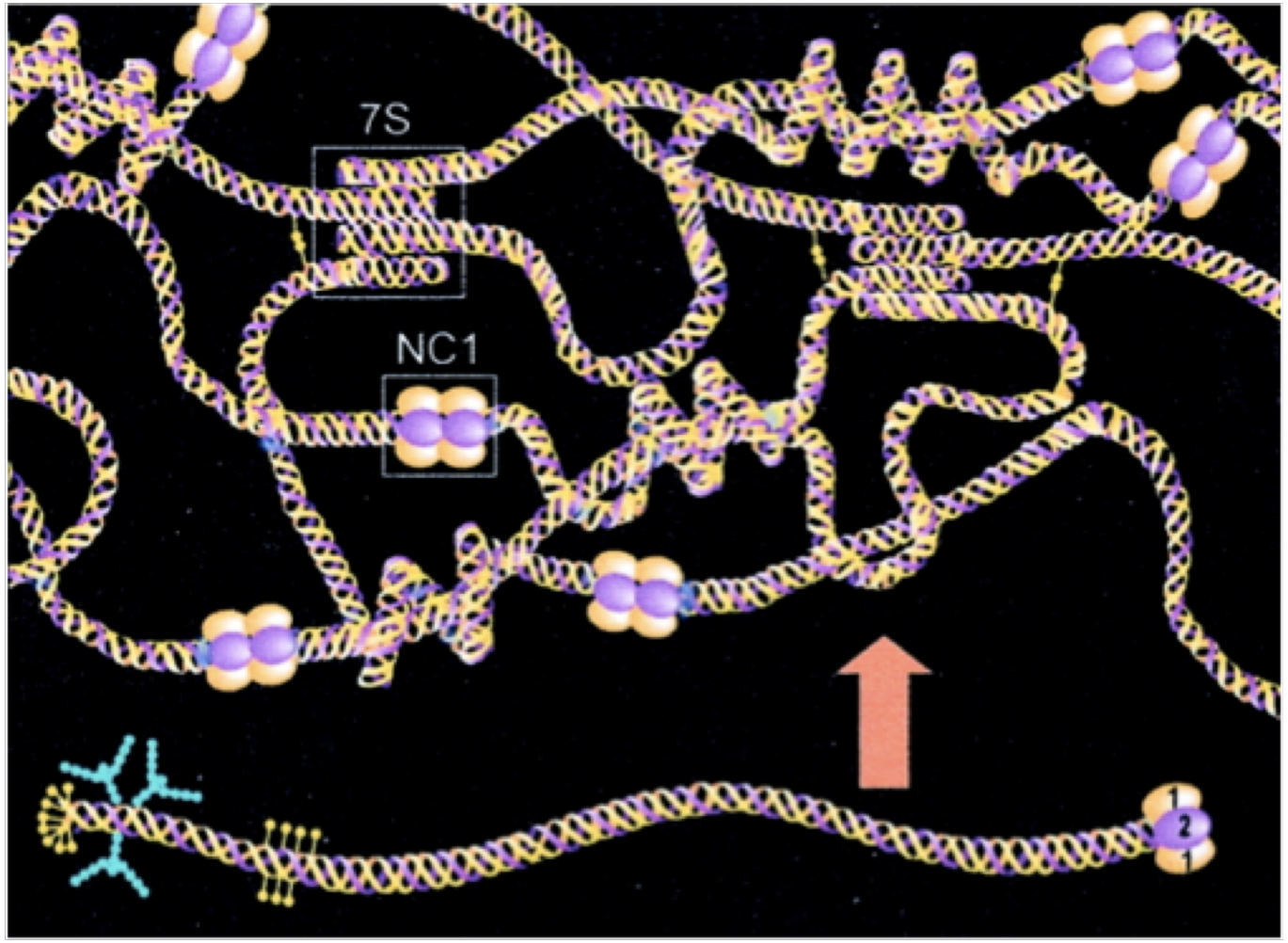

Collagen IV: alpha 1,1,2

↓

Collagen IV: alpha 3,4,5
Alport syndrome

Collagen IV: alpha 5,5,6

BG Hudson, JASN 2004

Red cell traversing the barrier

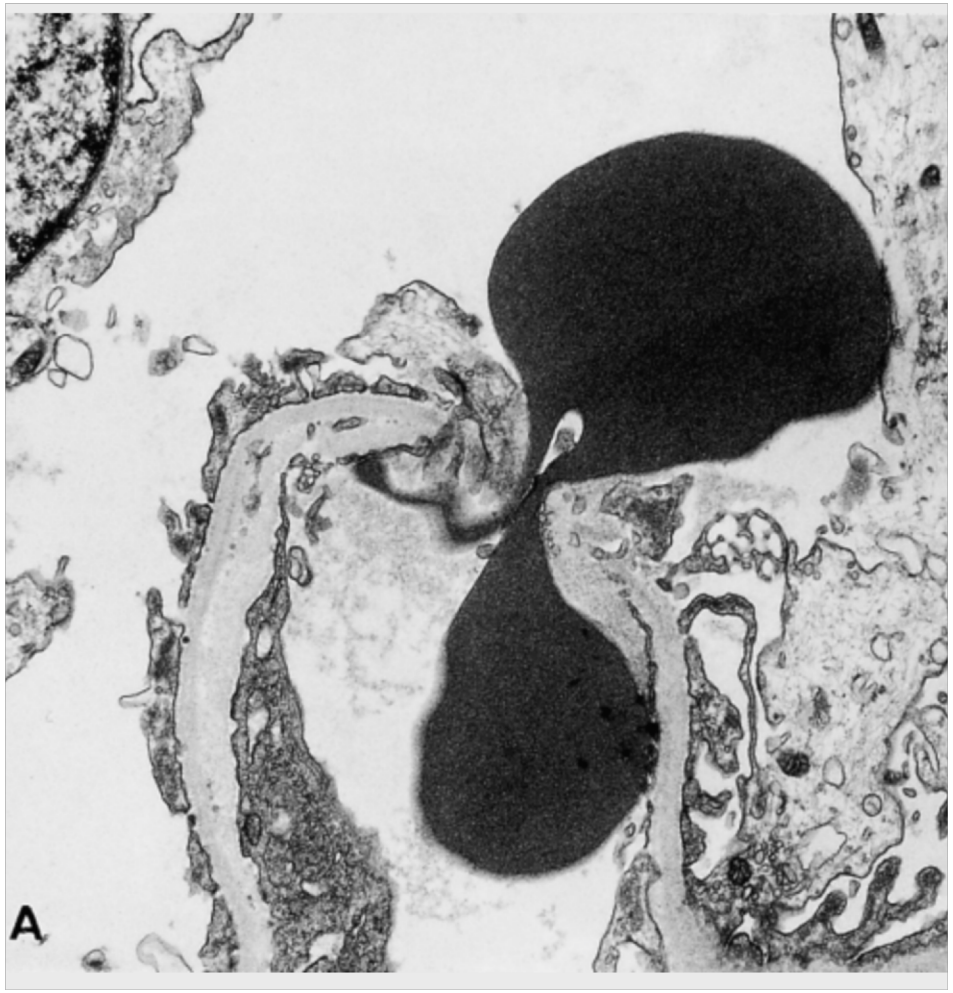

Collar JE, Ladva S, Cairns T and Cattell V:
Red cell traverse through thin glomerular basement membranes *Kidney International 2001*

Familial haematuria- genetics

- Alport syndrome
  - *COL4A3,4,5,6*
- Thin basement membrane nephropathy
  - *COL4A3,4*
- Epstein/Fechtner/Sebastian/May-Hegglin
  - Macrothrombocytopenia
  - *MYH9*
- Glomerulopathy with fibronectin deposits
  - *FN1*
- C3/CFHR5 glomerulonephritis
  - *CFHR5*
- More…

Alport syndrome

MANCHESTER 1824
The University of Manchester

- Macro/microscopic haematuria
- Rare: 1-5000-1:10000
- 1-2% of ESRD
- Mutations
  - *COL4A3,A4*- autosomal recessive
  - *COL4A5*- X-linked
  - Heterozygous mutation
- Impaired collagen IV assembly
  - kidney, inner ear and eye

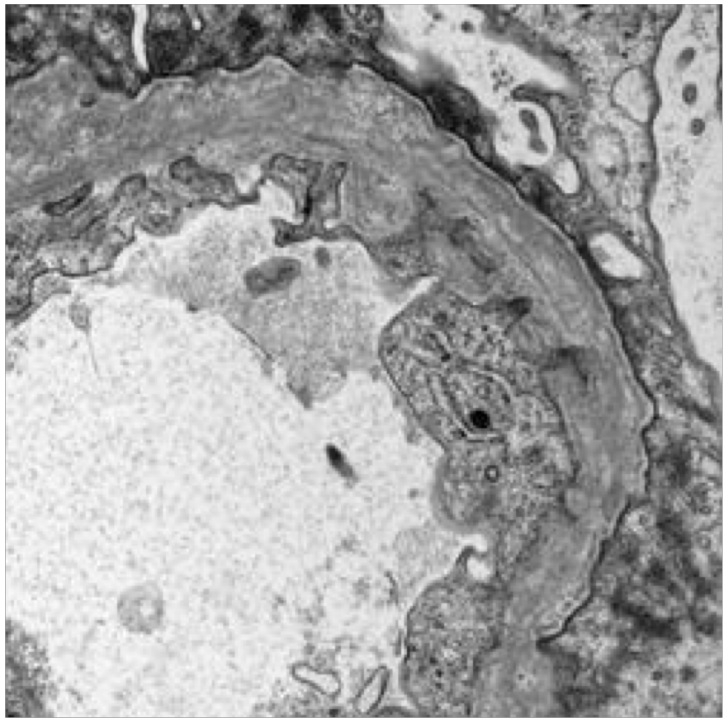

Irregular GBM, basket weave, lamellation

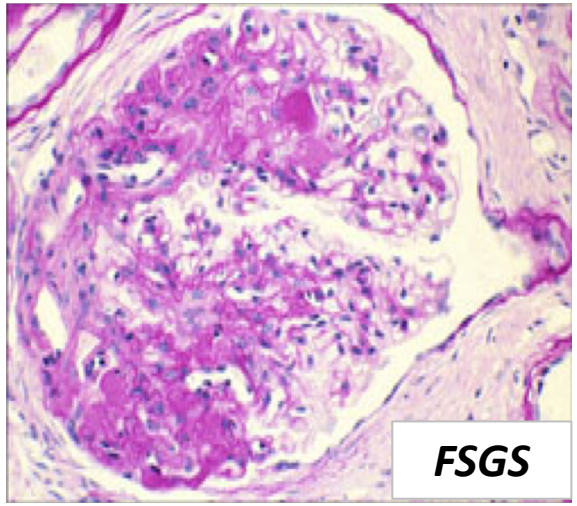

***COL4A3* Gene Variants and Diabetic Kidney Disease in MODY**

Yiting Wang,[1] Junlin Zhang,[1] Yingwang Zhao,[1] Shanshan Wang,[1] Jie Zhang,[2] Qianqian Han,[1] Rui Zhang,[1] Ruikun Guo,[1] Hanyu Li,[1] Li Li,[1] Tingli Wang,[1] Xi Tang,[1] Changzheng He,[3] Geer Teng,[4] Weiyue Gu,[5] and Fang Liu[1]

Diagnosis

- Macro/microscopic haematuria
- Family history
  - Chronic kidney disease
  - Deafness
- Renal biopsy
  - Basket weave GBM
- Eye signs
  - Anterior lenticonus
  - Macular flecks
- Hearing
  - High-tone sensorineural deafness

Not all patients are the same…

MANCHESTER 1824
The University of Manchester

- 2 year old male
  - Pyrexia, ‘cola’ coloured urine
  - Normal creatinine and immunology
  - Familial renal disease
  - Renal biopsy EM: Variable thickness GBM
  - Eye examination and audiometry normal
  - Mutation in ***COL4A5***

Electron microscopy

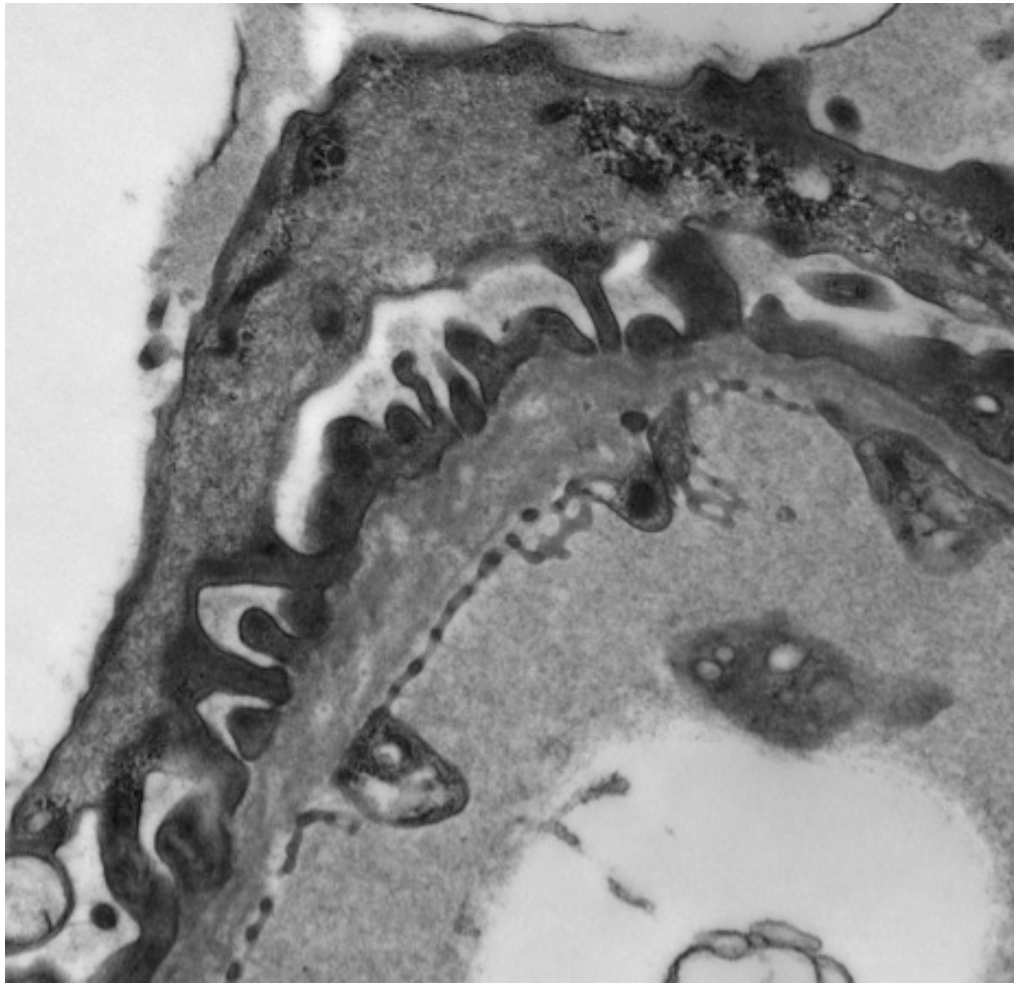

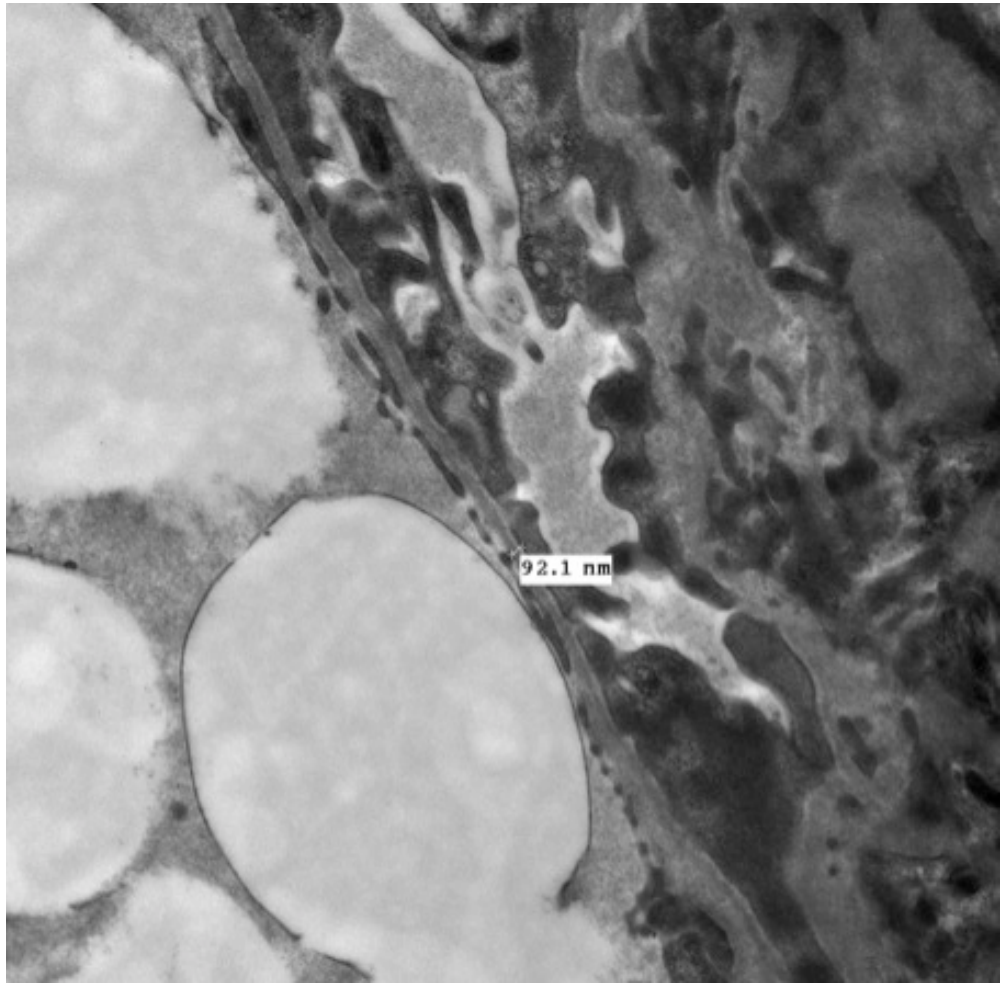

Basement membrane abnormalities

Sibling 1

- 8 year old female with ESRD
  - No renal biopsy
  - Dialysis and deceased donor transplant aged 9
  - Satisfactory graft function at age 17
  - Heterozygous mutations in ***COL4A5***
  - Eye examination and audiometry normal

- Further genetic analysis: skewed X-inactivation

Sibling 3

- 5 year old male
  - Fever, elevated creatinine
  - Persistent microscopic haematuria and proteinuria
  - No biopsy- family history known
  - Mutation in ***COL4A5***
  - Commenced ACE inhibition

Sibling 4

- 6 month old male
  - Facial swelling, macroscopic haematuria
  - Nephrotic syndrome
  - Daily 20% albumin replacement
  - 28 day trial of steroids
  - Renal biopsy: **GBM and podocyte abnormalities**
  - ACE inhibition
  - Commenced peritoneal dialysis aged 3
  - Mutation in ***COL4A5***

- Whole exome sequencing: Mutation in *MYO1E*

Family History

MANCHESTER 1824
The University of Manchester

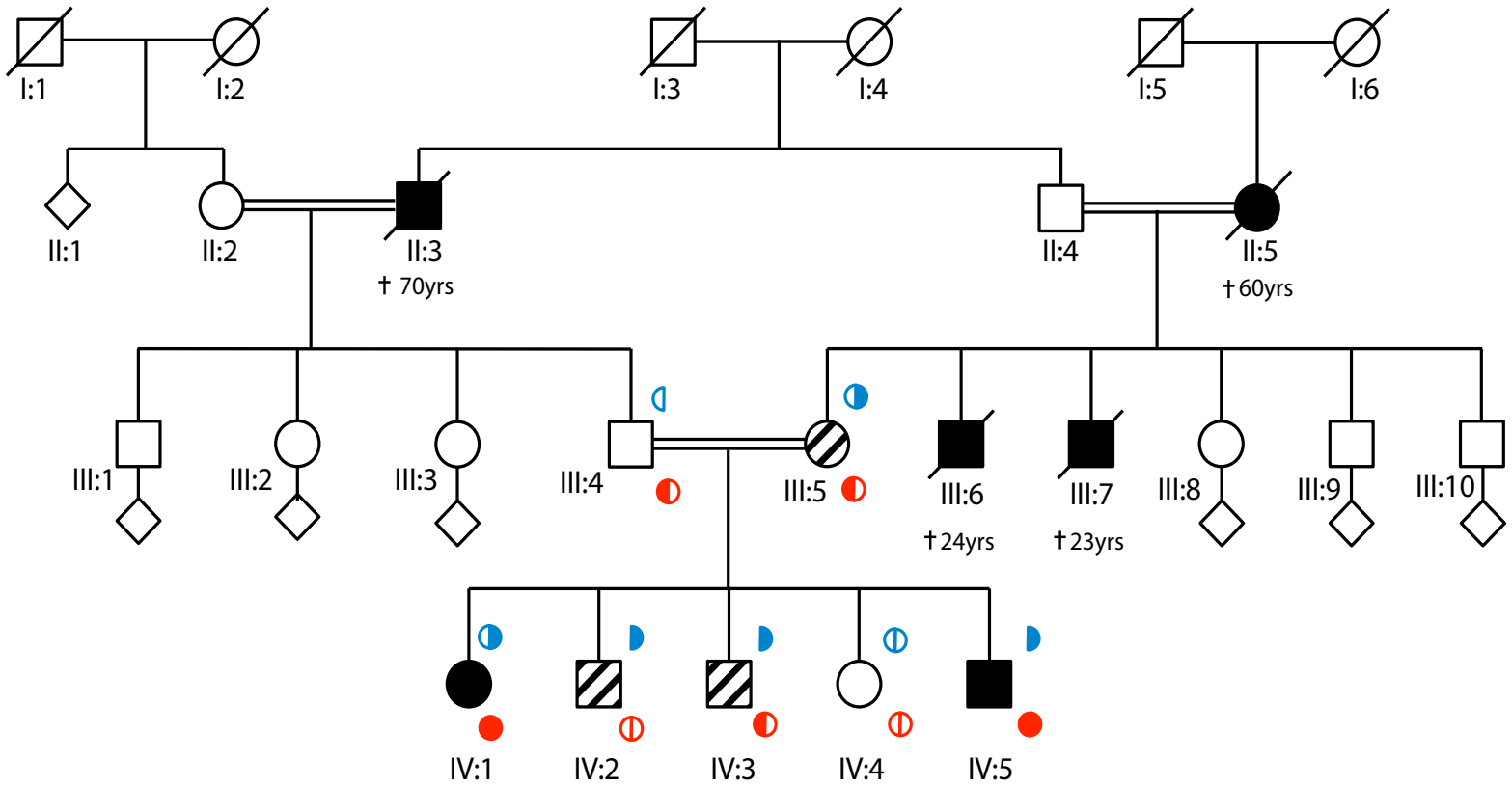

Haematuria, proteinuria

Renal failure

Top geneotype *COL4A5* (blue)

Bottom genotype *MYO1E* (red)

Common pathways

MANCHESTER 1824
The University of Manchester

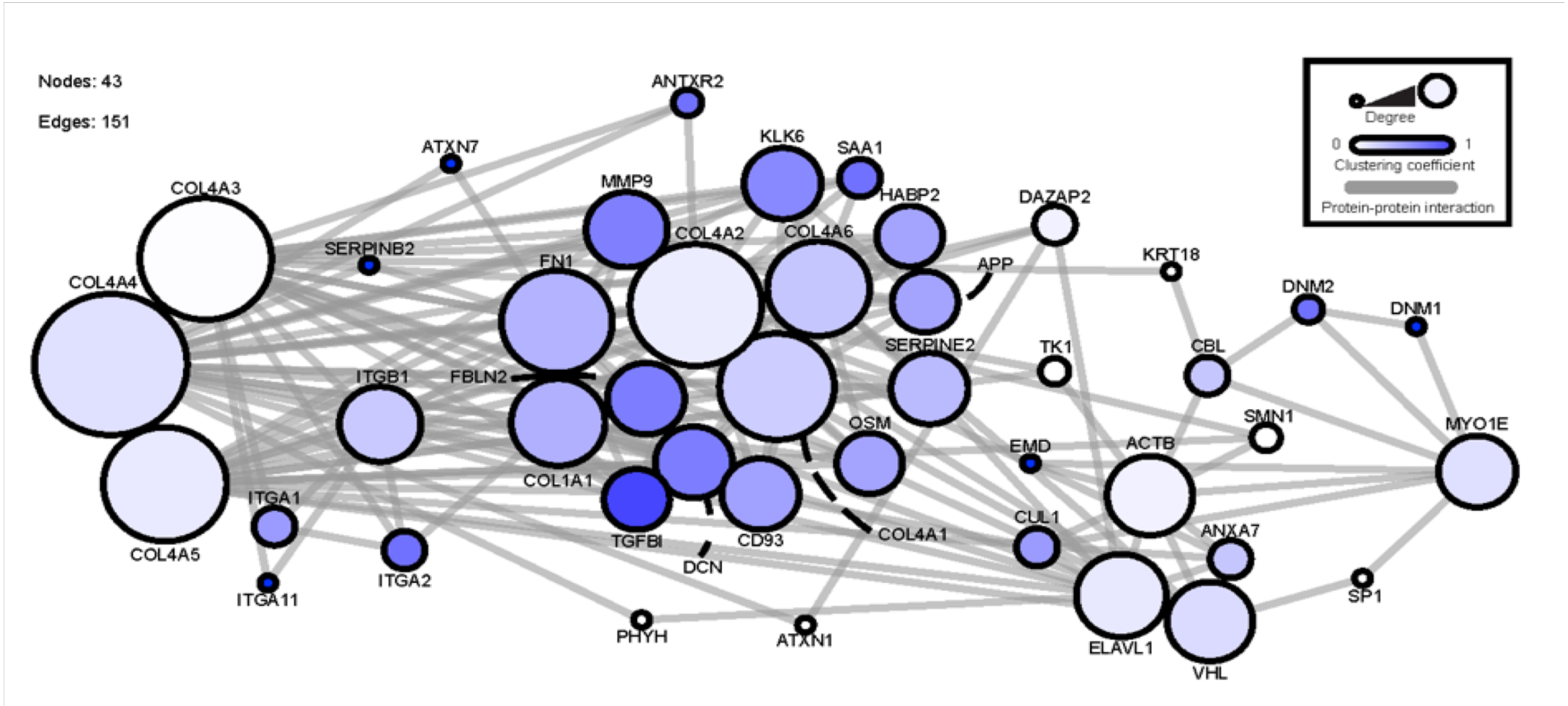

Lennon R, *et al*. Coinheritance of COL4A5 and MYO1E mutations accentuate the severity of kidney disease. *Pediatric Nephrol 2015*

Genetic testing

- NGS focused renal gene panels
  - *COL4A3,4,5 MYH9, CFHR5, FN1, NPHS2* etc
- 10-15% new mutations- no family history
- Advantages
  - Early diagnosis
  - Mode of inheritance
  - Phenotype prediction
  - Patient registry
  - **Avoid kidney biopsy**

Heterozygous mutations in *COL4A3/A4*

MANCHESTER 1824
The University of Manchester

http://www.kidney-international.org clinical investigation

see commentary on page 1081

Rare hereditary COL4A3/COL4A4 va
be mistaken for familial focal segm
glomerulosclerosis



Andrew F. Malone[1,2], Paul J. Phelan[1,2], Gentzon Hall[1,2], Umran Cetinc
Andrea S. Alonso[1,4], Ruiji Jiang[1,4], Thomas B. Lindsey[1], Guanghong W
Stephen R. Smith[2], Nicholas J.A. Webb[5], Philip A. Kalra[6], Adebowale
Shaw[8],
Peter J. Conlon[9], J. Charles Jennette[10], David N. Howell[11], Michelle P. Winn and
Rasheed A. Gbadegesin[1,4]

- Blood pressure

- **Lifelong surveillance**

Intervention

MANCHESTER 1824
The University of Manchester

Early angiotensin-converting enzyme inhibition in Alport syndrome delays renal failure and improves life expectancy

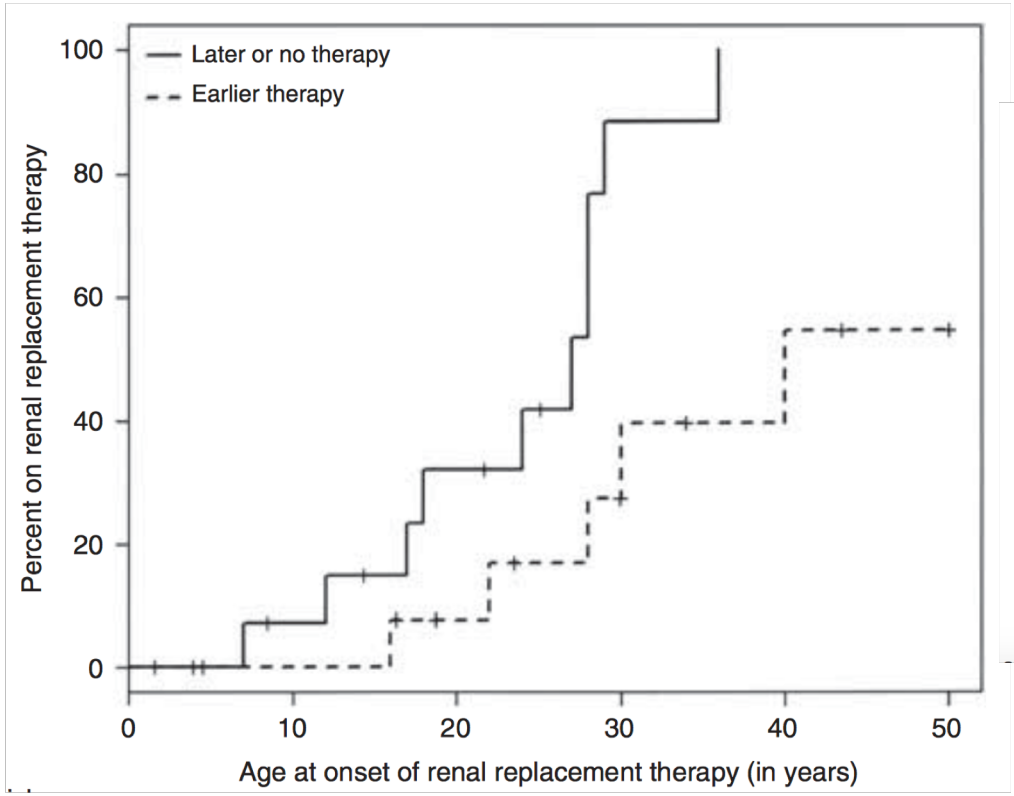

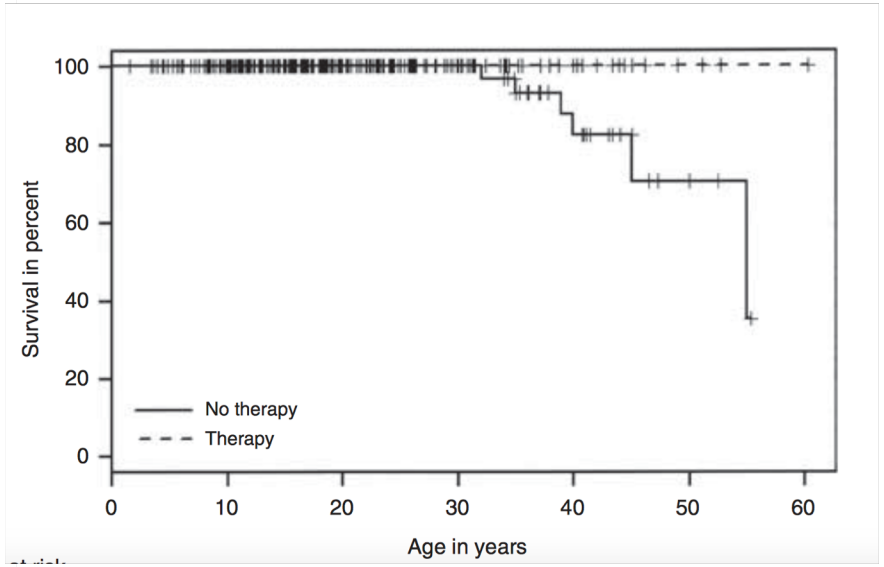

Oliver Gross *et al* Kidney International 2012

Intervention

MANCHESTER 1824
The University of Manchester

- RAAS blockade:
  - ACE inhibition/Angiotensin receptor blockade
    - *Savige J, Gregory M, Gross O, Kashtan C, Ding J, Flinter F. Expert guidelines for the management of Alport syndrome and thin basement membrane nephropathy. J Am Soc Nephrol 2013;24(3):364-75.*
- Current trials
  - Anti-miR 21: Fibrosis
  - Bardoxolone: *Perspective article: Baigent C, Lennon R. JASN 2018*
- Future trials

Summary

- Causes of microscopic haematuria
- Persistent glomerular haematuria is **not benign**
- Importance of genetic testing
- Patient registry
- Lifelong surveillance: BP and urinalysis
- Use of RAAS inhibitors for persistent proteinuria

ERKNet
The European
Rare Kidney Disease
Reference Network

Unravelling the pathophysiology of HUS in light of recent discoveries on complement activation

Guiseppe Remuzzi (Bergamo)

ERKNet Webinar: Nov 13, 4 pm (CET)